

# DIFFICULT BLOCKS AND REPROCESSING

## WHAT TO DO WHEN YOUR BLOCK WON'T SECTION



**Knowledge  
Pathway**



Advancing Cancer Diagnostics  
Improving Lives

**Leica**  
BIO SYSTEMS

## Author

Geoffrey O Rolls BAppSc, FAIMS  
Histology Consultant  
Leica Biosystems  
Former Senior Lecturer Histopathology  
Department of Laboratory Medicine  
RMIT University  
Melbourne

## Contributors

Fiona Tarbet

Kerrie Scott-Dowell

Alison Hopkins

Neville Farmer

Grant Taggart

# Introduction

From time to time, in all histopathology laboratories, paraffin blocks will be encountered that are difficult or even impossible to section. In some cases this may be due to the nature of a particular type of specimen and the tissue elements of which it is comprised. These elements can pose a problem even when properly fixed and processed. Fibroid, thyroid, heavily keratinised skin, nail and blood clot are examples of challenging specimens that can produce problem blocks. Sometimes problem blocks result from inadequate fixation, inappropriate or faulty processing - including over-processing - or an instrument fault during processing. In these situations isolated problem blocks may result or, in the worst case, a whole batch of specimens may be affected.

Usually when problem blocks are encountered an initial assessment is made to find out what went wrong, followed by an attempt to get sections by whatever means possible. Part 1 of this publication lists some questions to ask that might help you decide what caused the problem. To provide further assistance, Part 2 includes some descriptions of problem blocks related to possible causes and provides some examples of difficult blocks where the cause was known. This should help you decide what is the particular problem with your blocks. Some suggestions for obtaining sections from difficult blocks without reprocessing are described in Part 3 (Solutions 1–6).

Where sections cannot be obtained or when multiple blocks are affected re-processing may have to be considered. Re-processing techniques are described and evaluated in Part 3 (Solutions 7–10). When reprocessing is proposed it is vital to have thoroughly investigated the cause of the problem beforehand, as re-processing is inappropriate in some situations (such as when tissue is over-processed). It is also important to ensure, as far as possible, that the problem does not recur.


Part 4 discusses the effects and causes of poor processing in more detail and addresses the matter of compromise when deciding on a processing schedule. As every laboratory should have a reliable reprocessing method included in its standard operating procedures, Part 5 describes a straightforward method for validating reprocessing protocols.



# Knowledge Pathway

# Contents

<b>Part 1:</b> The initial assessment – why is my block difficult or impossible to cut? . . . . .	7
<b>Part 2:</b> Getting more information: examples of typical problems, and their causes. . . . .	11
<b>Part 3:</b> Detailed solutions for problem blocks . . . . .	41
<b>Part 4:</b> The root cause of processing problems and their prevention . . . . .	67
<b>Part 5:</b> How to validate a reprocessing method . . . . .	81
<b>Part 6:</b> Appendix . . . . .	85





## **Part 1**

# **The Initial Assessment**

**Why is my block difficult or impossible to cut?**






## The initial assessment – why is my block difficult or impossible to cut?

**When faced with blocks that are very difficult to cut or cannot be sectioned at all, it is important to try to work out what has gone wrong before deciding what to do. The first questions to ask are:**

1. What is wrong with the processed specimens? Are they too hard, too soft, brittle, mushy etc. The descriptions provided in Part 2 may help you decide.
2. What was different about the processing run that produced the problem specimens, compared to previous successful runs?
3. Was the intended schedule actually used?
4. Does my problem affect all the specimens in the batch, or just a small number? Are they all of a similar type?
5. Were my specimens at the very top of the retort and perhaps not fully immersed in all reagents?
6. Were my specimens processed using the usual schedule that generally produces good results for this size and type of specimen?
7. Is it likely that the schedule was too long or too short for my problem specimens? If the schedule was too long the tissues may be “over-processed”, too short a schedule will produce “under-processing”. Over-processed tissues should not be reprocessed.
8. Did the software show an error in the run that might indicate a processor malfunction?
9. Did a visual check of the reagent bottles help (levels, contamination, seating and sealing)?
10. Is there a possibility that an error was made when replacing solvents on the processor, or were any reagents outside their recommended purity thresholds? Faulty reagents or an incorrect reagent sequence can produce “under-processing”. If the appropriate instrument is available, the specific gravity can be measured to determine the approximate concentration of dehydrating agents.
11. Was normal fixation applied to the problem specimens?
12. Do I know with certainty, what has gone wrong?

These questions should help you determine what has gone wrong. If you remain uncertain as to the cause of the problem you must gather as much information as possible by carefully examining your specimens. Close examination of the blocks can confirm what you suspect may have happened. Your nose may help determine whether solvent remains in the tissue.



## **Part 2**

### **Getting More Information:**

**Examples of typical problems, and their causes**

## Getting more information: examples of typical problems, and their causes

Table 1 provides a quick reference to processing problems by listing some descriptive terms frequently used when histologists are confronted by difficult blocks and unsatisfactory sections. In each case a possible cause is suggested. In the following paragraphs each problem is described in detail with an accompanying example. The solutions listed are explained in Part 3 (Solutions 1 – 10). Further assistance is provided in the Reprocessing Decision Trees found in the Appendix.

**Table 1. Description of Problem Blocks with Possible Causes**

Number	Problem	Possible cause	Solution (see Part 3)
1	Crisp, crunchy or brittle tissue	Over-processing	1, 3
2	Shrunken tissue	Under-processed	8, 9
3	"Cooked" tissue	Over-processed	1, 2, 3
		Specimen dried out	7,
4	Sludgy, mushy or greasy tissue	Under-processed	9, 10
5	Dry and powdery tissue	Over-processing	1, 2, 3
6	Tissue smells of clearing agent	Under-processed	8, 9
7	Soft and compressible tissue	Under-processed	9, 10
8	Tissue contains hard fragments	Calcium or other material present	6, 3, 5
9	Outer rim of tissue satisfactory but central area will not section.	Under-processing	9, 10
		Incomplete wax infiltration	8
10	Tissue shows poor consistency throughout.	Poor fixation, faulty processing	9, 10
11	Outer rim of tissue is brittle and will not section while central area is satisfactory.	Over-processing	1, 2, 3
12	Specimen shows discrete areas that will not section, corresponding to particular tissue types such as muscle, dense connective tissue or fat.	Under-processing	3, 4, 5 then 9
13	Separation of the specimen surface from the surrounding wax. The specimen may be pulled from the block face during trimming.	Faulty embedding	8
		Under-processing	9,10
14	Shrinkage of the specimen producing a concave block face	Under-processing	9,10
15	Tissue at the centre of the block is poorly supported and sections show "blue hue" and "nuclear meltdown".	Under-processing or faulty processing	9
16	Sections "sweat" while floating	Under-processed or faulty processing	9d
17	Sections disintegrate rapidly while floating	Under-processing (retained solvent)	9




## **Problem 1. Crisp, crunchy or brittle tissue**

The tissue is likely to be over-processed. Reprocessing is unlikely to help. Soaking the block face in ice water or softening agent and careful re-cutting may produce an acceptable result (Use solutions 1 and 3).

### **Example**

These sections of liver shown during flotation in Figure 1, were very brittle to cut and initially cohesive sections could not be obtained. The tissue was processed on a 12-hour ethanol/xylene cycle, which was too long for this tissue type and for the dimensions of the specimen. Better sections were obtained after brief use of a softening agent on the block face (water with added detergent), chilling and re-cutting. (solutions 2 and 3)





**Figure 1**

Sections from a brittle block of liver

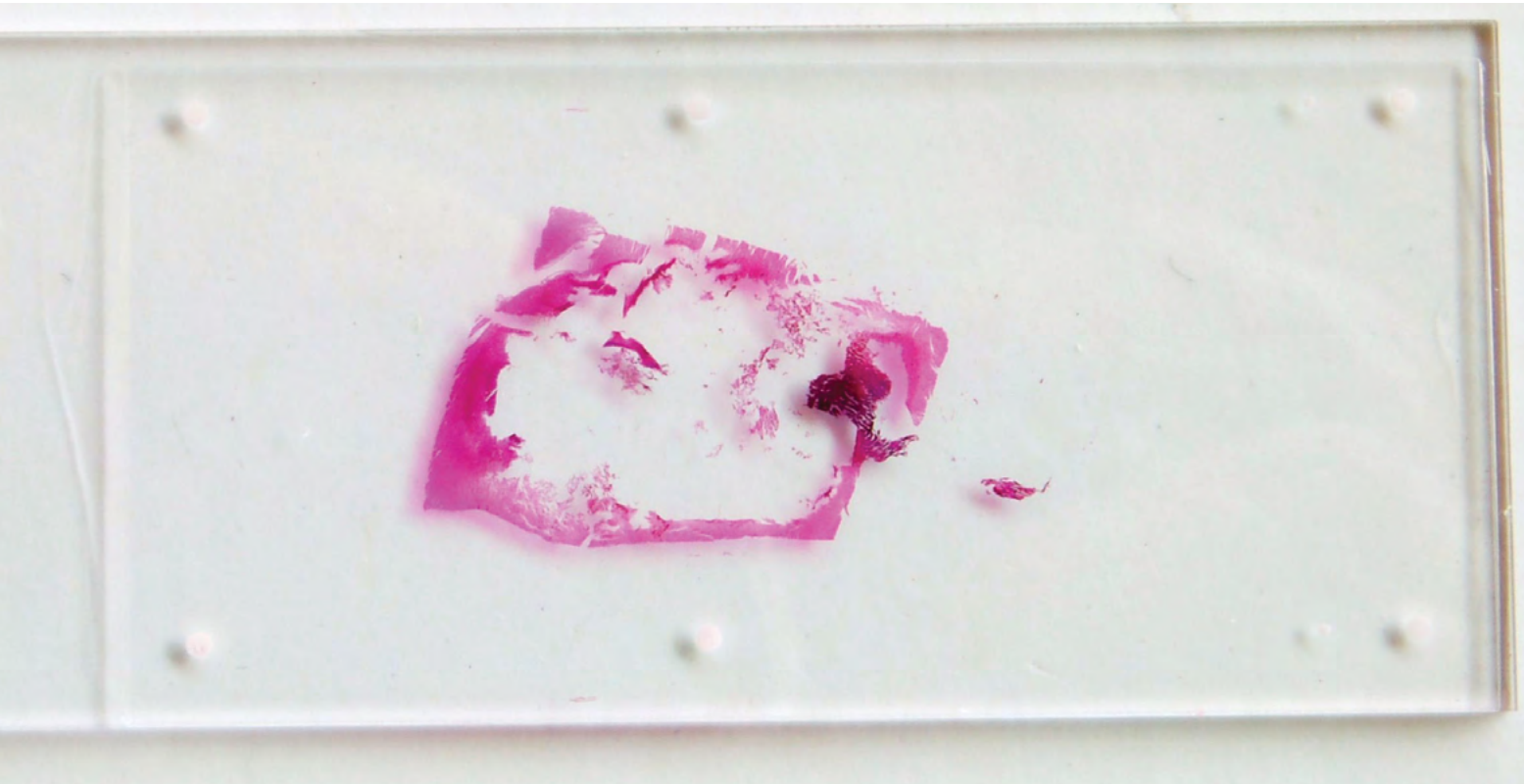
## Problem 2. Shrunken tissue

Under-processed tissue shrinks back into the block due to evaporation of residual solvent. Reprocessing may help. After sectioning, well-processed tissue does not shrink because all the solvents have been displaced by wax. (Use solutions 8 or 9)

### Example


The block shown in Figure 3 is under-processed heart muscle, sectioned 24 hours previously. The face of the block has contracted back as the tissue shrinks due to evaporation of residual solvent remaining after processing. The photograph has been taken to illustrate the extent of the shrinkage using back lighting (green) behind an angled mirror as shown in Figure 4. The best section that could be prepared from this block, immediately after it was embedded is shown in Figure 2.

The extent to which a block surface contracts after sectioning is a good indicator as to the quality of processing. In addition, the exposed tissue in this block smelt of clearing agent. This specimen was processed on a cycle that was too short for its size and nature. Use of Solution 9A may allow a complete section to be obtained.



**Figure 2**

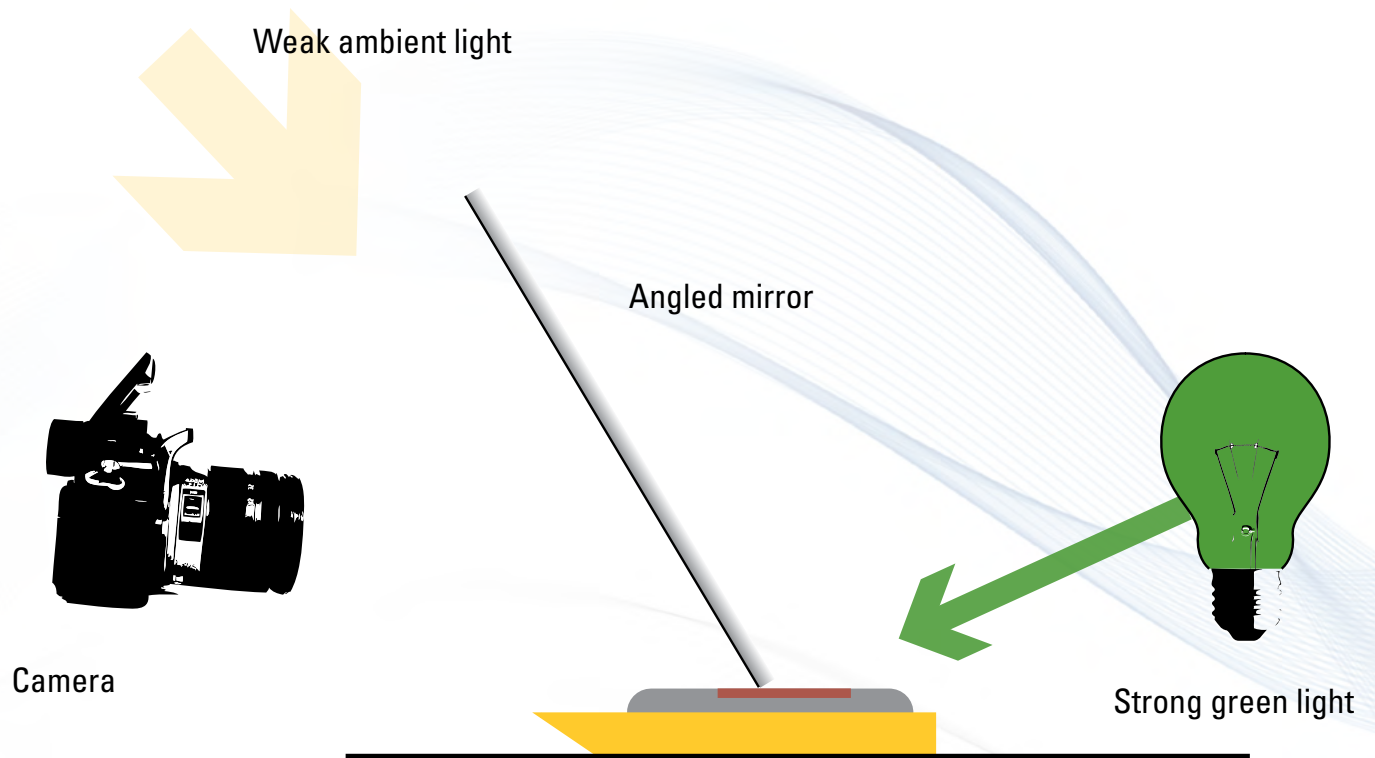
Poor section from the under-processed block of cardiac muscle shown in Figure 2



**Figure 3**

Block showing extreme shrinkage





**Figure 4**

Camera arrangement to demonstrate specimen shrinkage

### **Problem 3. “Cooked” tissue**

Tissue described in this way is usually over-processed (or has been subjected to extreme conditions e.g., excessive heat). The damage may be irreversible. Sections can sometimes be obtained by soaking the block face in ice water or softening agent and carefully re-cutting. (Use solutions 1, 2 and 3). See also the example in Problem 1.

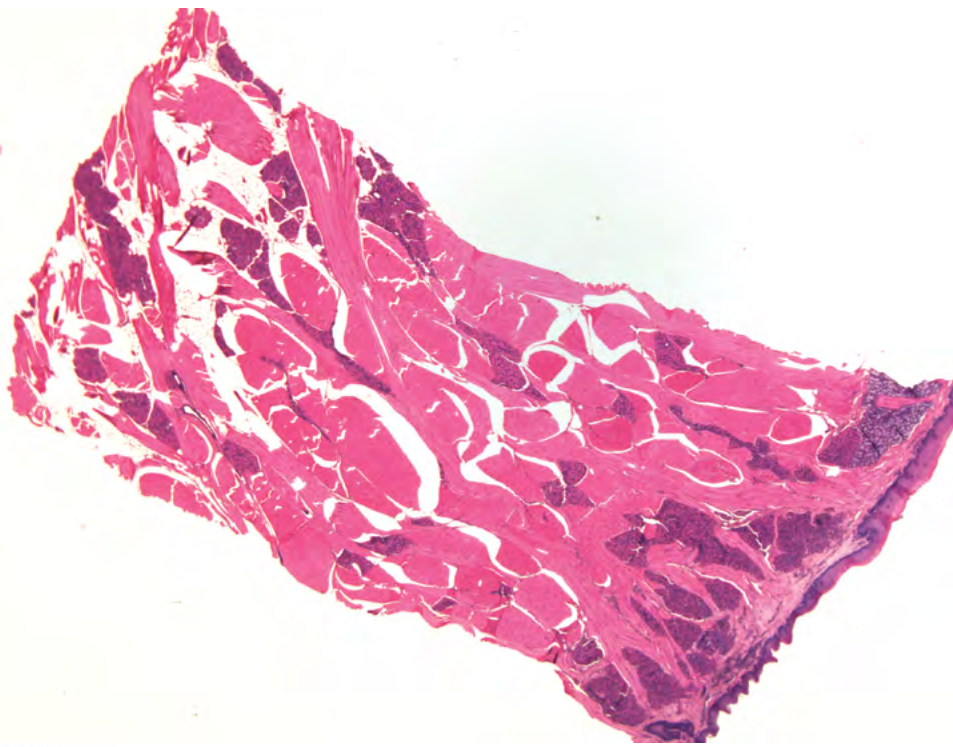
This effect can also be caused by total drying of the specimen before or during processing. Use of a reconstitution solution followed by reprocessing may be of value. (Use solution 7)

#### **Example**

A specimen of tongue was dried out for one week prior to routine processing. At embedding it appeared shrivelled and very hard and was described by the embedder as “cooked”. After applying Solutions 1, 2 and 3, the best section that could be obtained is shown in Figure 5.

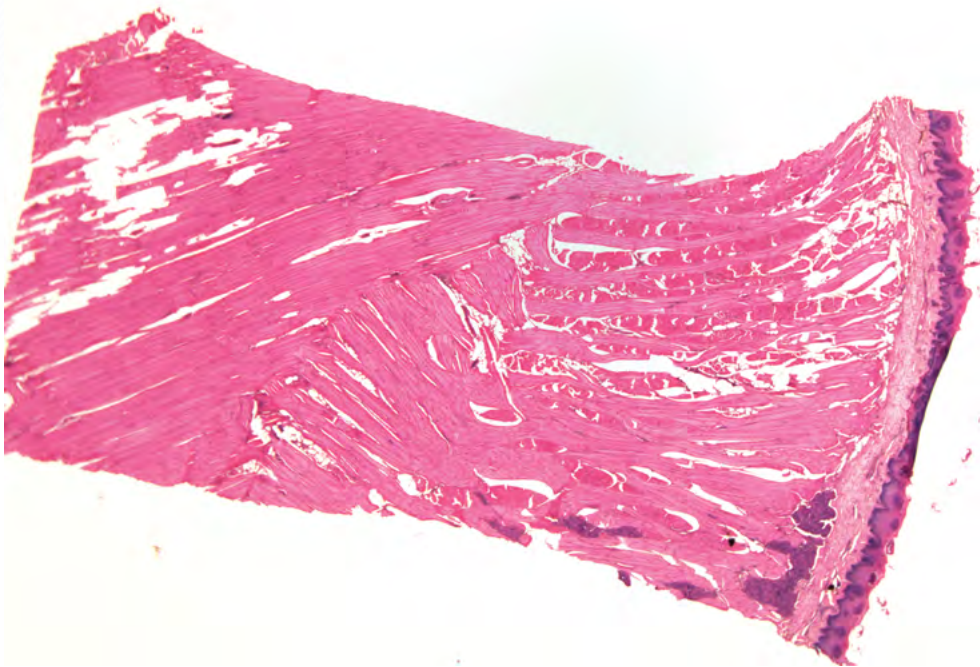
The result of applying solution 7, using Sandison’s solution to reconstitute the specimen followed by reprocessing and re-cutting, is shown in Figure 6. Although the morphology is only fair a much more cohesive section was obtained.





**Figure 5**

Section of tongue before reconstitution and reprocessing



**Figure 6**

Section of tongue following reconstitution and reprocessing

## Problem 4. Sludgy, mushy or greasy tissue

The usual cause of blocks with these properties is fat. Processing has failed to remove lipid from areas of the specimen and these areas have not been properly infiltrated with wax and are unsupported for cutting. This is commonly encountered with large breast specimens that have been processed using too short a cycle. Reprocessing, using a schedule of sufficient length, should produce blocks that can be sectioned. (Use solutions 9 or 10)

### Example

Figure 7 shows an under-processed fatty breast specimen with a large central area that appears oily.


Only a rim of fragmented tissue can be transferred to the slide (Figure 8). The tissue is neither dehydrated nor cleared (contains undissolved fat) and must be reprocessed. Solution 9a using an eight-hour cycle is suggested.





**Figure 7**

Under-processed breast specimen



**Figure 8**

Rim of fragmented tissue from an under-processed breast block

## Problem 5. Dry and powdery tissue


Dry and powdery tissues can be the result of over-processing, particularly if the tissue contains a lot of blood. It is also frequently observed when rodent tissue is processed on excessively long schedules. Reprocessing will not help.

Soaking the block in ice water prior to cutting is useful. Cutting the block very slowly after allowing it to warm a little may allow sections to be obtained. Cutting at a thinner thickness setting may help. (Use solutions 2 or 3)

### Example

Figure 9 shows a section from an over-processed block of rodent liver (reticulin stain). The tissue was processed on a 12-hour cycle and the resultant block was extremely brittle, dry and powdery and showed extensive micro-cracking. Soaking the block face in ice water before re-cutting may produce better sections (solution 3).





**Figure 9**

Over-processed rodent liver (reticulin stain)

## Problem 6. Tissue smells of clearing agent

Blocks that smell of clearing agent are under-processed. The solvent has not been displaced by wax. Re-infiltration of the specimen with wax may produce blocks that can be sectioned but, because specimens like this often contain traces of water, complete reprocessing may be the best option. (Use solutions 8 or 9)

### Example

The section from a block of fibrous tissue shown in Figure 10, disintegrates as soon as it is placed on the water surface. Although the microtommist managed to get a section it was extensively disrupted. The block face smelt of xylene that had not been displaced with wax. Solution 8 would improve the block and allow cohesive sections to be obtained.





**Figure 10**

Sections on the water surface disintegrate due to residual solvent

## Problem 7. Soft and compressible tissue

When tissue in a block is soft and compressible it indicates that, for some reason, wax infiltration is incomplete. Often the cause is the presence of undissolved lipid not removed during processing (under-processed tissue) but the cause could simply be insufficient wax infiltration. Often the cause is undissolved lipid but the cause can simply be incomplete infiltration. Reprocessing is the best option. (Use solutions 9 and 10)

### Example

The block of pancreas pictured in Figure 11, shows some of the typical effects of a short fixation time followed by serious under-processing. The micrographs (Figures 12 and 13) demonstrate the drastic consequences to the morphology shown in sections from this block. It is surprising that any sections at all could initially be obtained. The block face has contracted away from the surface over several days following sectioning of the tissue, due to evaporation of solvents that were not eliminated during processing.

The typical gross cracking that occurs in the centre of an under-processed block is shown in Figure 12. The outer rim of the tissue is better preserved.

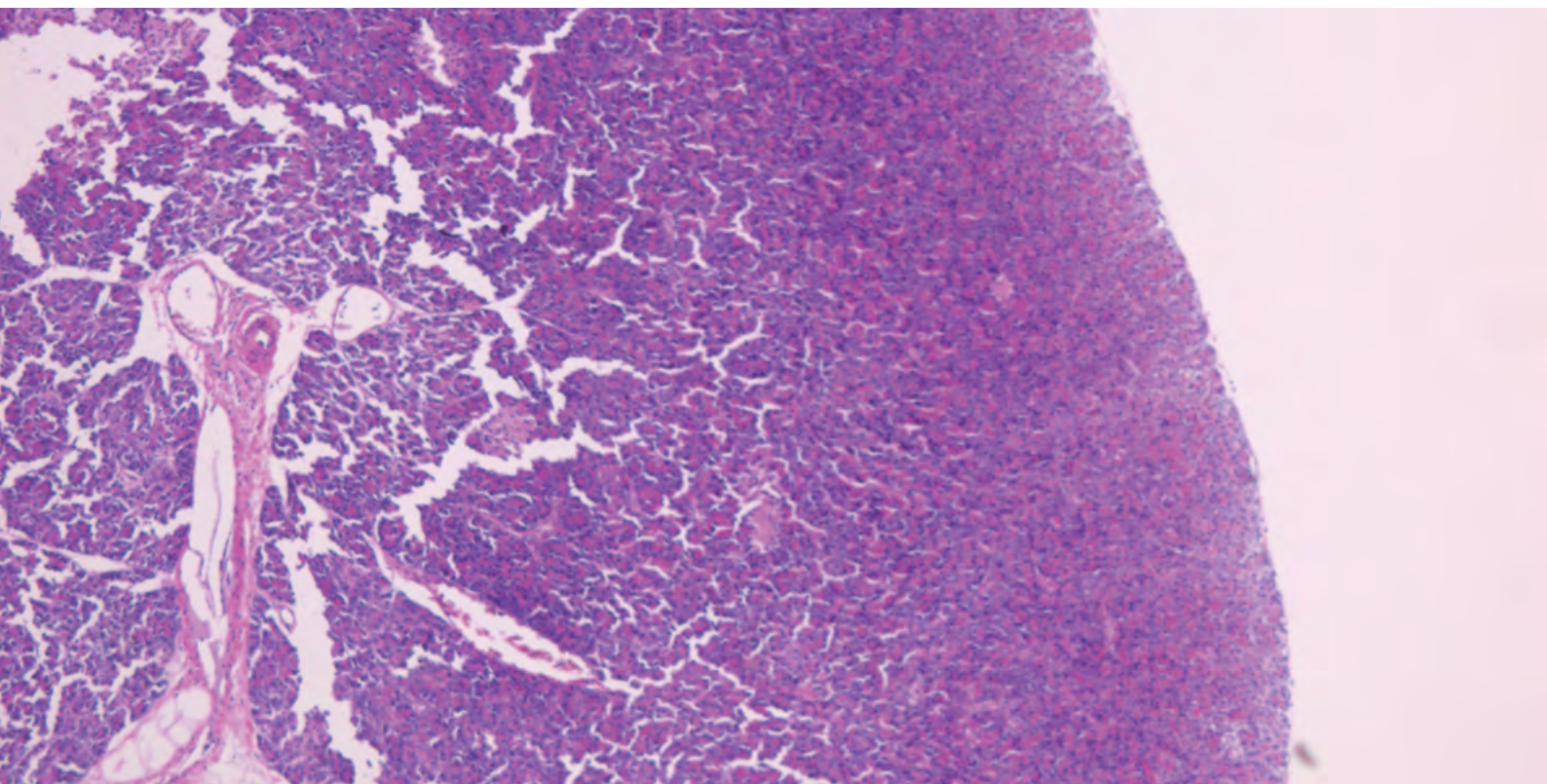
A central area where cells are swollen and demonstrate typical “blue hue” is shown in Figure 13. Retained solvent is one of the causes of this problem where tissue has had insufficient dehydration and clearing and the clearing solvent has not been replaced with wax.<sup>1</sup> Solution 10 would allow better sections to be obtained but it is likely that the morphology would still be compromised to some extent.



**Figure 11**

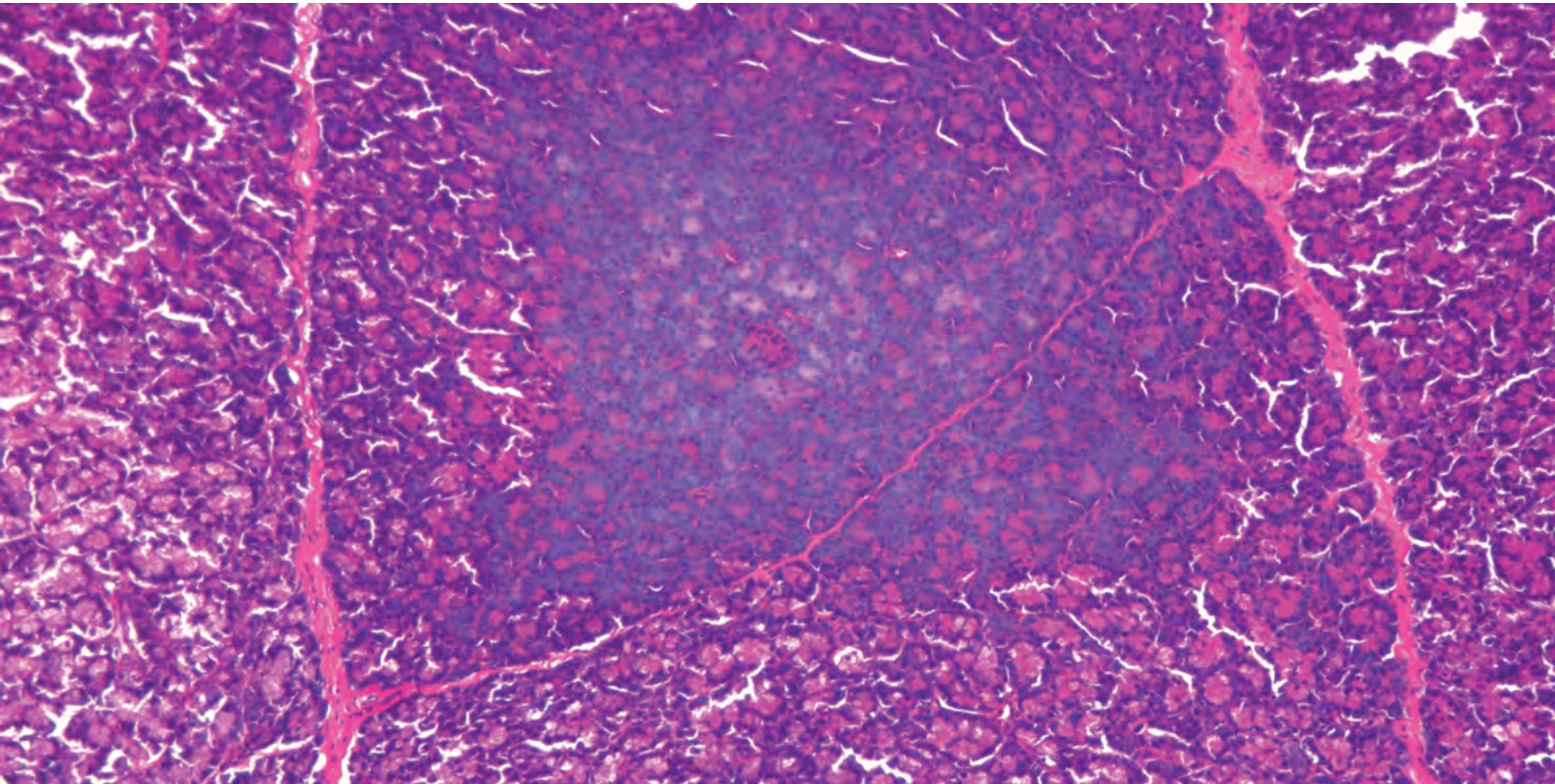
Block of poorly-fixed and under-processed pancreas





**Figure 12**

Low-magnification view of poorly-fixed and under-processed pancreas



**Figure 13**

A central area from the poorly-fixed and under-processed pancreas showing "blue-hue".



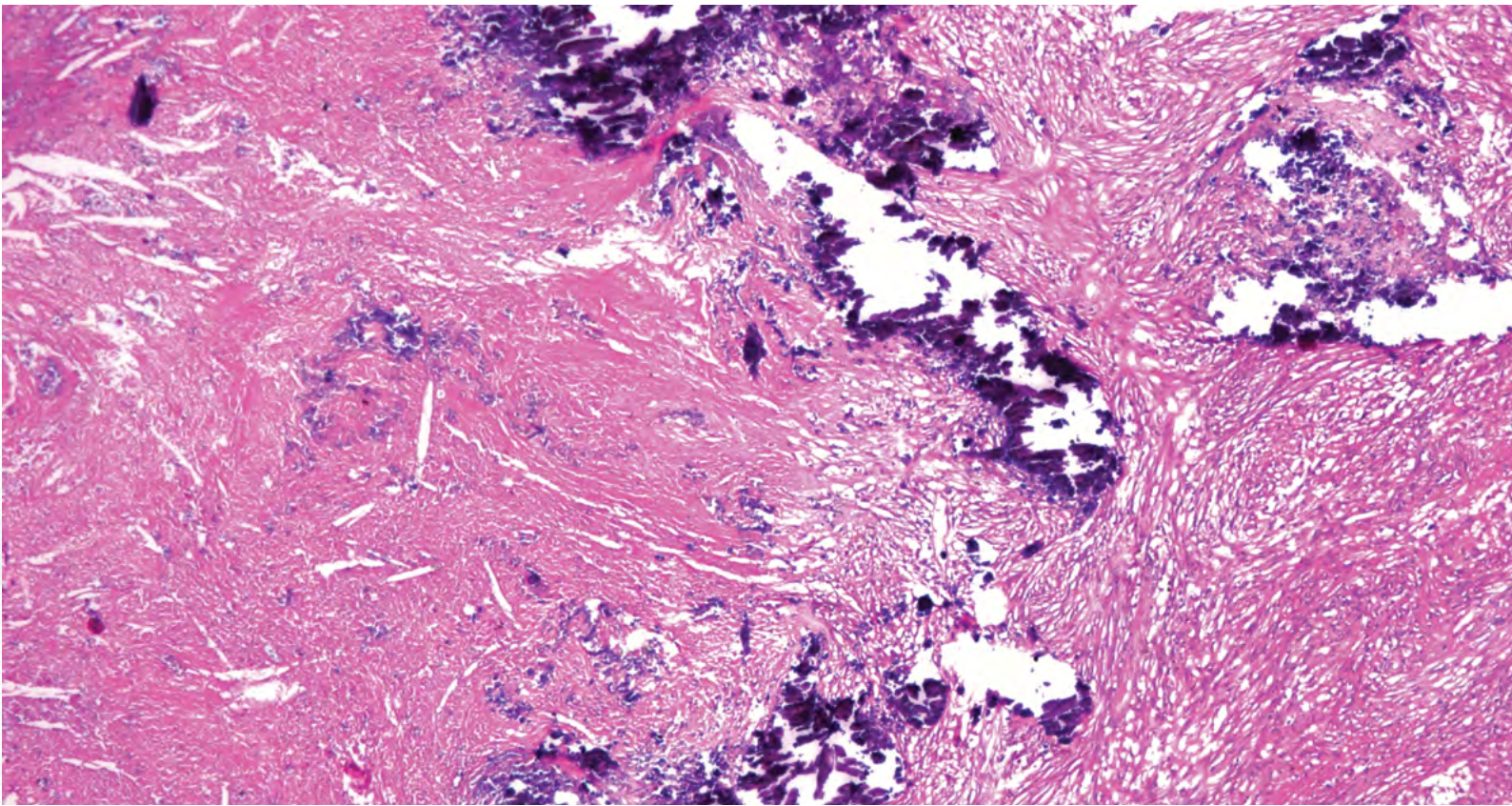
## Problem 8. Tissue contains hard fragments

First, try to decide what the fragments are likely to be. If calcium is present, surface decalcification followed by thorough washing of the block and re-cutting should produce useable sections. There are many other possibilities including atheromatous plaques. These may benefit from soaking of the block face prior to recutting. Other mineral deposits, generally in lung tissue, can cause problems. Local physical removal of offending particles or foreign bodies may be a last resort (eg surgical staples, glass, bitumen fragments etc.). Use solutions 6, 3 and 5.

### Example

The basophilic material present in the granuloma shown in Figure 14 is calcium. Much of it has fragmented and fallen from the section. This micrograph was taken from the best preserved part of the section. The remainder was badly shredded. Surface decalcification (Solution 6) may have permitted a few cohesive sections to be obtained. Re-processing would be of little value unless it included a decalcification step.





**Figure 14**

Granuloma containing basophilic calcium (H & E)

## **Problem 9. Outer rim of tissue satisfactory but central area will not section**

Indicates under-processing. The tissue is not completely dehydrated and/or cleared and is therefore not properly infiltrated (the wax could not penetrate due to the presence of water). Reprocessing should help. (Use solutions 9 or 10)


Another possibility is that the specimen has been properly dehydrated and cleared but has had insufficient exposure to wax to produce complete infiltration. Melt down the block and apply additional infiltration. (Use solution 8)

### **Example**

The block of liver shown in Figure 15 contains a central area that will not section. The tissue is unsupported and falls out as the blade passes through.


On close examination the central area is dry and powdery and is not infiltrated with wax (Figure 16). The tissue was thoroughly fixed but, as it was processed on a short two-hour cycle it has not been properly dehydrated or cleared. If a complete, cohesive section is to be obtained, it will require reprocessing. Solution 9d would be used to reprocess it using a six hour schedule.





**Figure 15**

Poorly processed liver that will not produce a cohesive section



**Figure 16**

Liver block with an unsupported central area

## **Problem 10. Tissue shows poor consistency throughout**

It must be remembered that initial poor fixation of the specimen can cause this problem. It can also be due to a processing problem, but may not necessarily be caused by simple under-processing (schedule too short). It is more likely to be caused by poor quality, contaminated (over-threshold) reagents or wrongly ordered reagents. Were solvents recently replaced? Reprocessing may overcome the problem. (Use solution 9 or 10)

### **Example**

The cerebral cortex specimen shown in Figure 17 has been processed using a conventional 12 hour ethanol/xylene schedule. Although this schedule should be quite adequate for a specimen of this type and dimensions, the texture of the block is poor. On investigation it was discovered that the final dehydrating ethanol was heavily contaminated with water. Thus the specimen is poorly processed. Solution 9 (reprocessing) may improve the quality of the sections obtained.





**Figure 17**

A dehydration fault in a block of brain

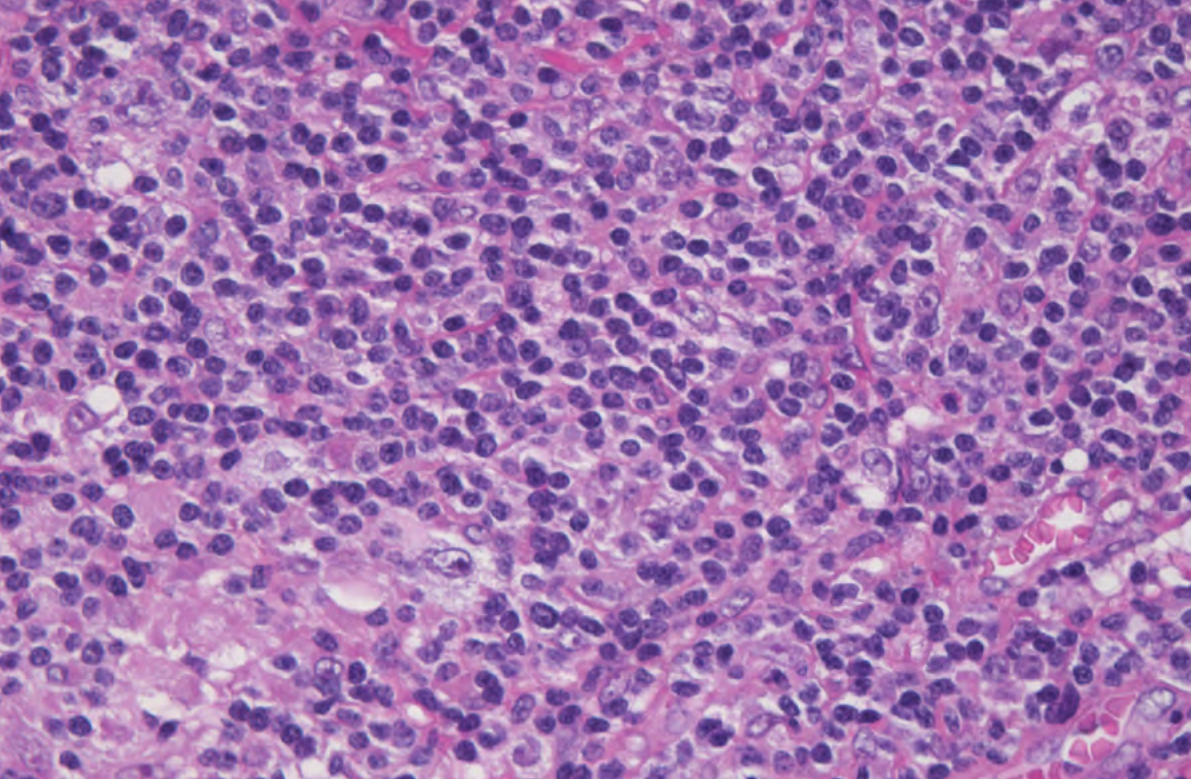
## **Problem 11. Outer rim of tissue is brittle and will not section while central area is satisfactory**

This may indicate over-processing in susceptible tissues such as hematopoietic or lymphoid tissue where the outer layer of tissue is the first affected. Reprocessing is unlikely to help. Soaking the block face in ice water or softening agent and carefully re-cutting may produce an acceptable result. (Use solutions 1, 2 and 3)

### **Example**

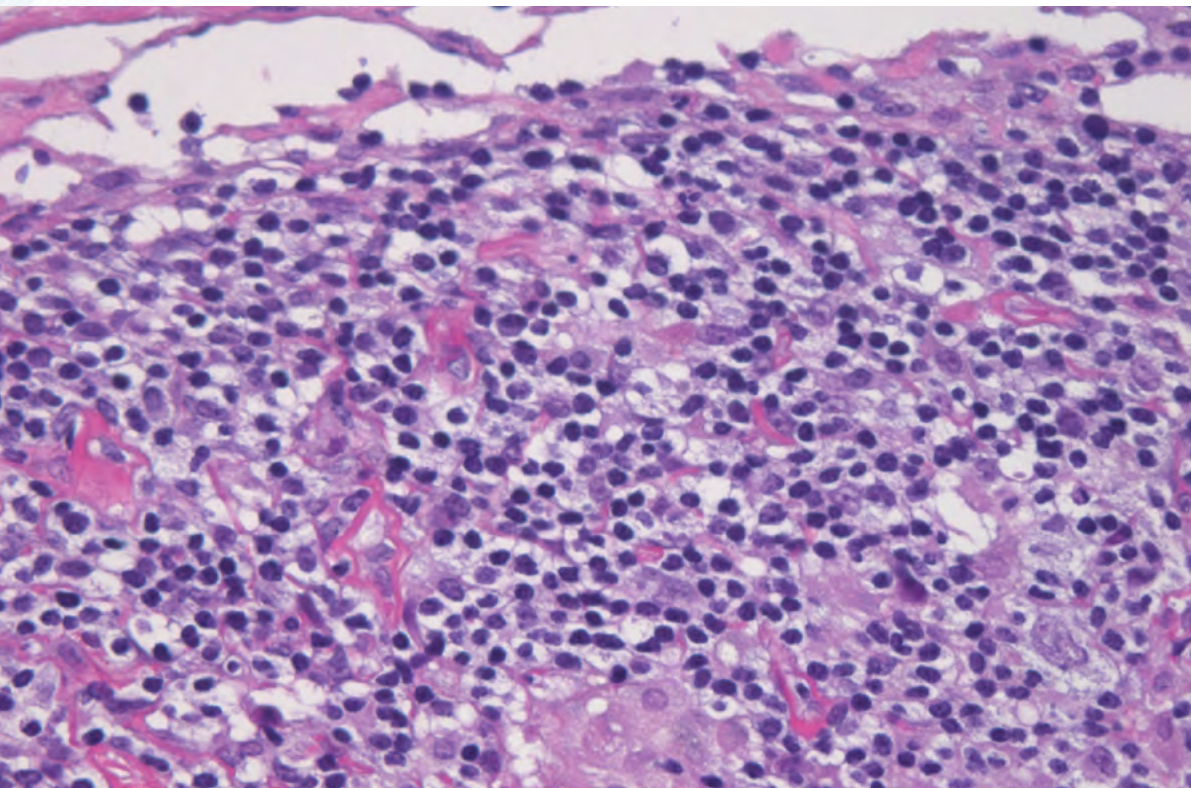
The micrographs shown in Figures 18 and 19 represent different areas from the same section of spleen. Figure 18 shows the central area that sectioned well, while Figure 19 shows an area from the edge of the specimen that was brittle to cut. The central portion is fairly well preserved with the cytoplasm and nuclei of lymphocytes well shown with minimal shrinkage but the outer portion shows cracking, poor cytoplasmic and nuclear detail and substantial shrinkage. This block was over-processed, showing the morphological consequences of this in the outer part due to prolonged exposure to processing reagents. The central area has had less exposure to processing reagents and is better preserved. Solutions 1, 2 and 3 may help get better quality sections but reprocessing will be of no help.





**Figure 18**

Adequate processing in central area of spleen specimen



**Figure 19**

Over-processing of outer perimeter of spleen specimen

## **Problem 12. Specimen shows discrete areas that will not section, corresponding to particular tissue types such as muscle, dense connective tissue or fat.**


This indicates under-processing of susceptible tissues due to their unique characteristics (such as their extreme density). It might be worthwhile to first try the softening and cutting techniques detailed under solutions 1 - 5. If this is unsuccessful reprocessing may overcome the problem (solution 9)

### **Example**

Figure 20 shows a block of well-fixed but under-processed pig liver that was extremely hollow, due to shrinkage of the tissue. Careful examination also shows that the interlobular connective tissue is dry and unsupported in the centre of the block.

The section cut from this block (Figure 21), shows a large area of missing tissue and is quite unsatisfactory. This specimen was processed on a cycle that was too short and is neither properly dehydrated, or cleared. Use of solution 9A may allow a complete section to be obtained but the final morphological quality is likely to be only fair.





**Figure 20**

Block of pig liver showing poorly supported interlobular connective tissue



**Figure 21**

Under-processed pig liver with unsatisfactory central area

## **Problem 13. Separation of the specimen surface from the surrounding wax. The specimen may be pulled from the block face during trimming**

This could indicate a simple embedding problem. Wax on the specimen surface has been allowed to solidify before positioning the specimen in the embedding mould. Careful re-embedding would overcome this problem.

Extreme under-processing can also produce this effect as the specimen shrinks when solvent evaporates from the block face, causing separation of the specimen surface from the wax (See the example in problem 7). Thorough reprocessing can overcome this problem.

### **Example**

The specimen shown in Figure 22 has separated from the surrounding wax. This situation can result in the specimen being pulled from the block-face during microtomy (especially during roughing). It may have been caused by allowing wax to solidify on the specimen surface before positioning it in the mould during embedding. Careful re-embedding would overcome this problem. In this case the problem was not caused by poor processing.



**Figure 22**

Tumor specimen showing an embedding fault

## **Problem 14. Shrinkage of the specimen producing a concave block face**

Under-processing (or faulty processing) produces this effect as the specimen shrinks when solvent evaporates from the block face. Thorough reprocessing can overcome this problem. This effect occurs over several days following embedding and is sometimes seen in blocks that have been cut and filed. See examples 2, 7 and 12. (Use solutions 9 or 10)



## **Problem 15. Tissue at the centre of the block is poorly supported and sections show “blue hue” and “nuclear meltdown”**

If the problem is due to under-processing resulting in retained solvent in the block, reprocessing may help. If poor nuclear demonstration has resulted from other causes (such as formalin contamination of wax), reprocessing is unlikely to improve the morphology but may permit a better section to be prepared. (Use solution 9 or 10)

Nuclear meltdown (bubbling) is one of a number of descriptive names given to a group of artefacts which are characterized by poorly demonstrated cell nuclei. The causes of these artefacts are poorly understood, having been the subject of ongoing debate for many years.<sup>2,3</sup> Because there are a number of possible contributing factors the precise cause of a particular incidence may be impossible to pin down.

The characteristics of nuclear meltdown may include:

- » Poorly defined nuclear membranes
- » Chromatin which lacks definition (it may appear amorphous, like cut glass, or blurry, and can range from very pale to quite dense)
- » The presence of a blue hue or blue haze (more of a royal blue than the purple/blue of properly stained nuclei in the same section)
- » A patchy distribution which may affect only small parts of the section (for example, in a section of intestine or skin it may be present in only some areas of the epithelium with underlying tissues unaffected)
- » Appearance in a variable number of specimens in a batch ranging from one or two to many
- » Appearance in particular types of specimens only. Common specimens affected are: gastro-intestinal tract (particularly endoscopies), lymphoid tissue and bone marrow, spleen, skin and endometrium. Epithelial and lymphoid tissues appear to be most susceptible.
- » Periodic occurrences, troubling a laboratory for a time and then mysteriously disappearing only to reappear weeks or months later.

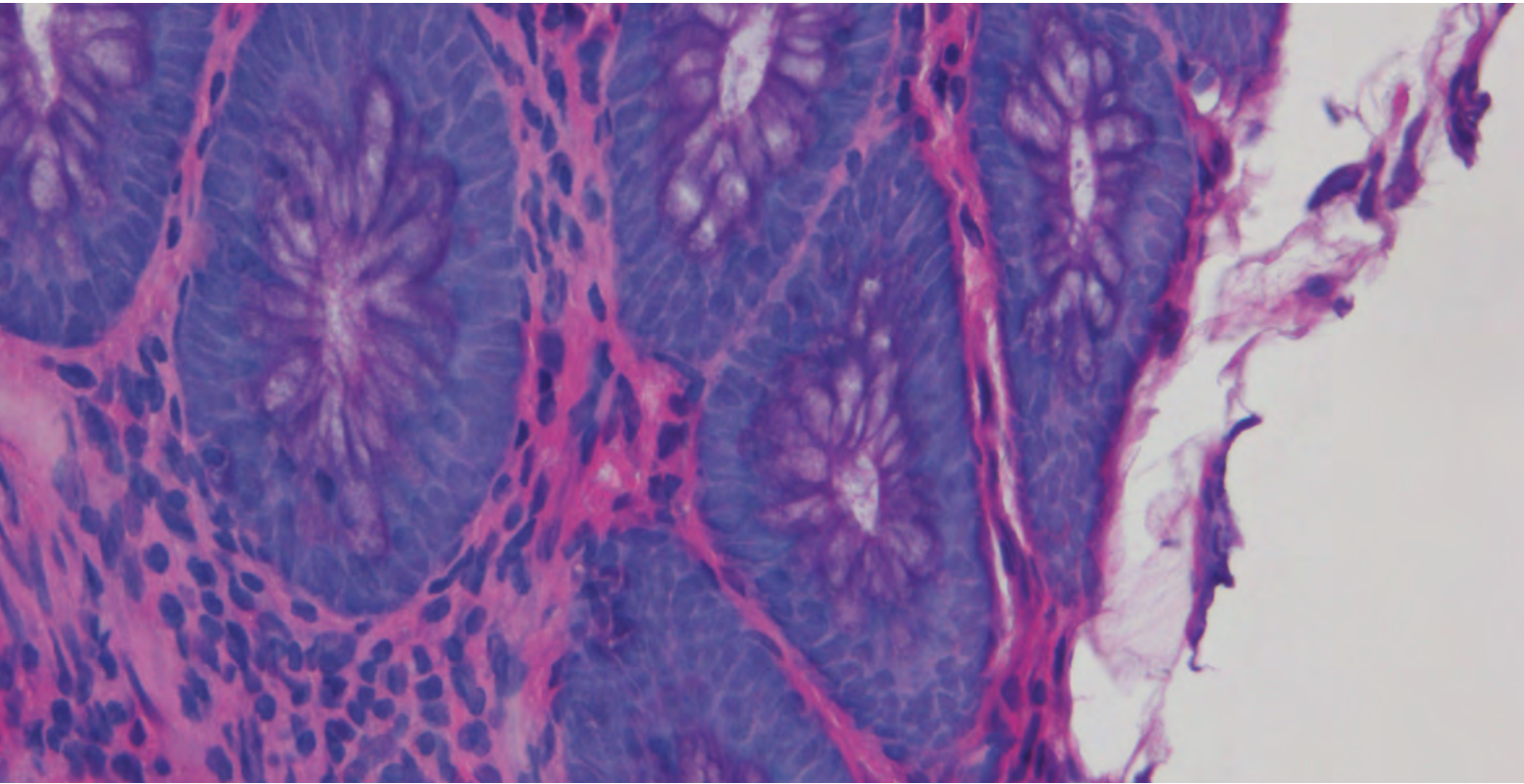
The following are some of the causes which have been suggested:

- » Allowing a specimen to dry out before fixation<sup>4</sup> ( eg. by placing fresh, unfixed tissue on a dry absorbent surface). This can certainly be a problem with tiny endoscopic specimens.
- » Using xylene which is contaminated with water during the clearing step during processing. In this situation it has been suggested that the problem can be overcome by reprocessing the specimen<sup>5</sup>.
- » Using wax which is contaminated with formalin or formalin and ethanol during processing<sup>5</sup>. This problem can be caused by a faulty tissue processor (particularly a fluid-transfer machine) and appears to permanently damage the tissue.

- » Failing to completely replace solvent with wax during processing (retained solvent). This may be caused by using a protocol that is too short, using expired or contaminated reagents or by a tissue processor fault. In this case reprocessing the specimen may overcome the problem).
- » Over-heating the section when drying prior to staining (faulty slide dryer producing hot-spots in section).
- » Impairing the staining of nuclei by ineffective dewaxing of sections prior to staining leaving traces of wax in the section. The nuclei fail to stain properly with haematoxylin and may take up eosin producing so-called “pink disease”<sup>6, 7</sup>. Extended dewaxing time and fresh solvent may overcome this cause of the problem.

### Example

Figure 23 shows the typical features of nuclear meltdown with the chromatin being very poorly defined with the presence of a hazy blue hue. A portion of the mucosa was affected in this way with some adjacent areas being normally preserved. The specimen was well-fixed post mortem material processed on a four-hour cycle. In this case we believe the problem was caused by retained solvent in the tissue (severe under-processing). Solution 9E would produce a more cohesive section and a better stain.



**Figure 23**

Mucosal tissue showing typical "blue hue"




## Problem 16. Sections “sweat” while floating

“Sweating” describes a translucent appearance sometimes observed in sections during flotation. This is sometimes associated with tiny oily droplets of clearing agent on the section surface. It is commonly seen in brain and spinal cord blocks that have been incompletely dehydrated and cleared. Sections with this appearance are also inclined to fragment after brief flotation. If sections cannot be obtained reprocessing may help. (Use solution 9d)

### Example

Figure 24 demonstrates sections from a block of brain showing “sweating” – an indication that the tissue was not fully dehydrated and cleared during the six-hour cycle used. In this area the section showed microscopic fine cracking and disruption. Brain is difficult and delicate tissue to process. Solution 9d may produce better sections but in this case improvement may be marginal.



**Figure 24**

Sections of brain showing "sweating"

## **Problem 17. Sections disintegrate rapidly while floating out**


This is a common problem usually caused by under-processing where retained solvent seems to break down the surface tension that normally holds the tissue together. As a consequence the section can rapidly disintegrate as it floats out. Floating the sections briefly on cold or tepid water and avoiding hot water altogether may allow sections to be salvaged. Where satisfactory sections cannot be obtained reprocessing can be used. (Use solution 9). See also the example in Problem 6.



## **Part 3**

# **Detailed Solutions**

## **Detailed solutions for problem blocks**



## Detailed solutions for problem blocks:

### What do I do now?

Before making a final decision you should have:

- » Carefully examined the tissue processor physically and for error messages and faults.
- » Talked with staff who had an involvement in processor maintenance, or setting and loading the instrument on this occasion.
- » Looked carefully at the resultant specimens and decided what is the most likely cause of the problem.
- » Considered whether it might be best to try to get some sections, even if they will be of poor quality, before attempting to reprocess.

Experienced histologists use a range of techniques to obtain sections from sub-optimal blocks. The more common methods are described in solutions 1–6 below.

There is no single method that will salvage all poorly processed tissue. The scientific and technical literature contains some suggestions and there is anecdotal support for some of these<sup>8-19</sup>. We have evaluated the options described in Solutions 7–10 below, but can only provide general advice, not specific suggestions, as the causes of processing problems are so diverse and success usually depends on correct identification of these causes. The reprocessing decision trees found in the appendix provide further help in decision making.



## Solutions without reprocessing

### Solution 1: Good basic technique

Make certain that you use good basic technique when trying to get sections from a difficult block. This includes:

- » Using a sharp, defect-free blade suitable for the type of specimen you are cutting.
- » Setting an optimal clearance angle for the blade (sometimes a small adjustment prevents sections being lifted off the blade on the upstroke).
- » Choosing an appropriate section thickness (sometimes cutting a little thinner or thicker will help). This is especially useful when blocks are brittle.
- » Ensuring your microtome is well-maintained and free of wear, with all clamps operating effectively (this is particularly important when large block faces or tough tissues are being cut).
- » Ensuring the specimen is optimally embedded with due attention to specimen orientation to the knife edge. For example for specimens such as cervix, which is very dense and fibrous, it is preferable for the blade to encounter a point of tissue rather than a long straight edge as it initially passes from wax to tissue. In such a block the wax is considerably softer than the infiltrated cervical tissue and this can produce thickness variations in the section due to movement of the blade or blade clamp. This can be avoided by appropriate orientation.
- » Ensuring that the block is cold.

### Solution 2: Chilling blocks

For routine paraffin sections it is standard practice to chill the block after exposing the tissue surface. The effect of chilling is to harden the wax so that it better matches the hardness of the infiltrated tissue. There are various methods for chilling blocks before taking sections but some are more effective than others, particularly with difficult blocks.

- » A freezer at  $-15^{\circ}\text{C}$  can be used but this provides a “dry” cold and sometimes causes cracks at the tissue/wax interface. These can make it difficult to get cohesive sections, particularly from difficult blocks
- » A refrigerated plate can be used and if its surface is wet it is most effective ( $0 - 4^{\circ}\text{C}$ )
- » For difficult blocks placing the block face in contact with the surface of melting ice is an effective means of chilling. This has the advantage of at least partially re-hydrating a thin layer of exposed tissue, which may allow a couple of sections to be obtained from a problem specimen (see below).
- » A pressurized cold spray can be used directly on the block face. This must be done carefully because localized freezing can cause cracking. Note also that some products may not be environmentally friendly.

## Solution 3: Soaking and softening

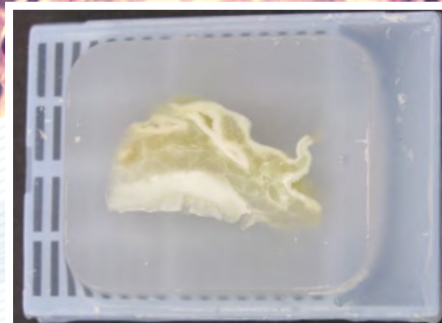
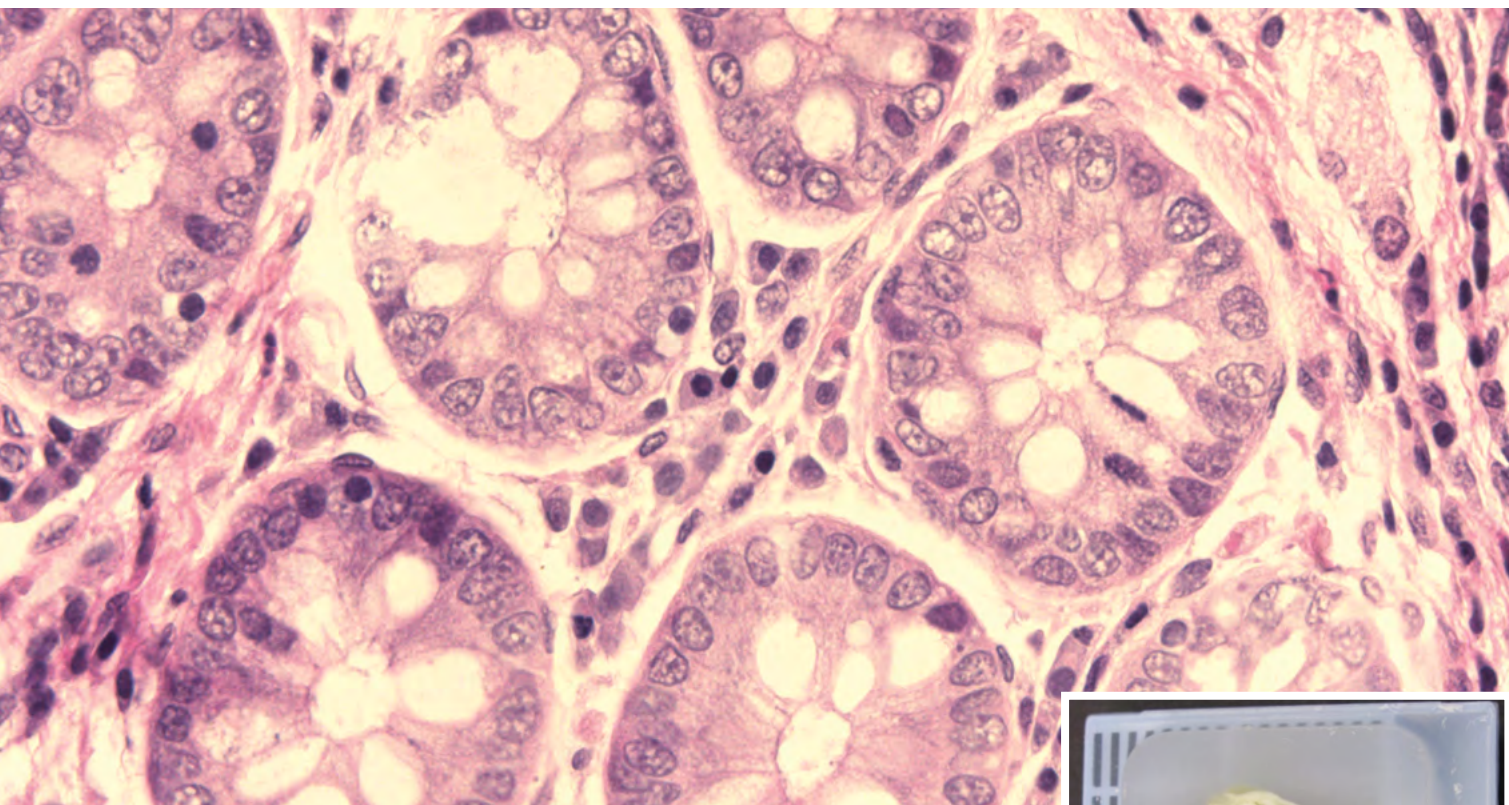
When tissue is exposed on the surface of a paraffin block by rough trimming it has the capacity to absorb water and other aqueous and alcoholic reagents. They will penetrate a small distance into the tissue softening and swelling it. With poorly processed tissue (both under- and over-processed) this effect may allow a couple of sections to be cut. Appendix Table 5 contains details of various reagents that can be used for this purpose.

With difficult blocks the procedure entails very careful trimming to expose the tissue while avoiding too much damage to the specimen surface, then placing it face down in a dish containing the softening agent for an appropriate time. The block face may then need to be rinsed and the block re-chilled before attempting to obtain some sections. Because only a very thin layer of tissue will have been penetrated by the reagent, it is vital that alignment of the block face in the microtome is preserved so that no tissue is wasted in obtaining a full-face section. Generally, after this procedure, the best quality sections are achieved by cutting very slowly. Options include:

- » Soaking the block face in ice water
- » Soaking the block face in cold water with added detergent<sup>6</sup> or fabric softener<sup>11,20</sup>
- » Soaking the block in a softening agent such as alcohol-glycerol mixture<sup>11</sup>, or Mollifex<sup>11,21</sup>
- » For heavily keratinised skin or nail specimens treat block face with Nair or Veet (hair removal products), potassium hydroxide solution or phenol solution (these are toxic chemicals and must be used with care). These reagents can also be used to soften thoroughly fixed tissue prior to processing<sup>22</sup>.

## Caution:

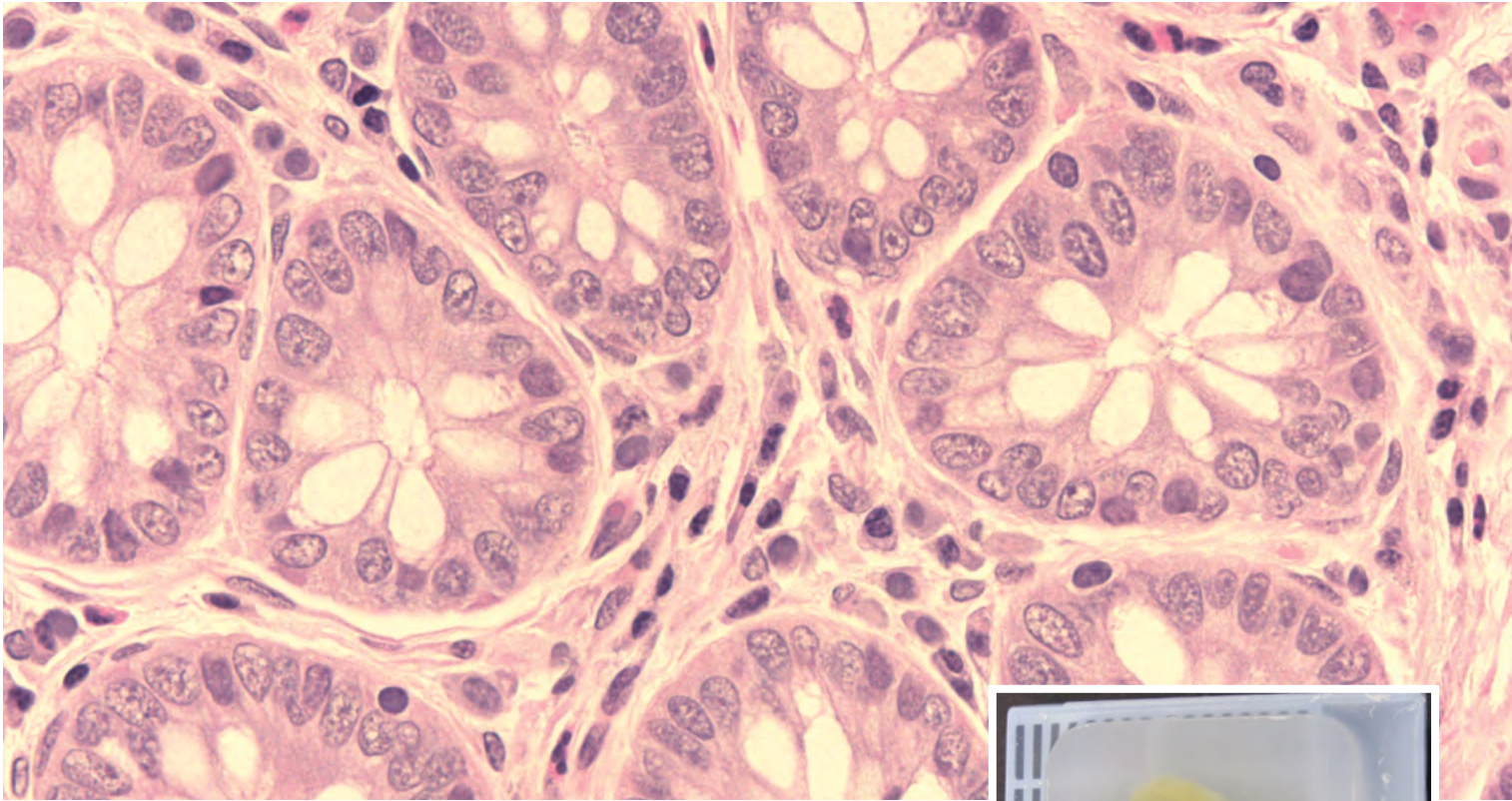
Prolonged soaking of blocks can damage the morphology and staining characteristics of tissues and should therefore be used conservatively. Figure 25A shows the effect of prolonged soaking in water. The tissue in the block has become white and opaque and there is nuclear damage and cellular shrinkage visible in the section when compared to the untreated block and section shown in Figure 25B.



**Figure 25A**

Block face soaked in water for 30 minutes





**Figure 25B**

Block face chilled briefly and sectioned without soaking

## **Solution 4: Non-standard flotation**

Non-standard flotation techniques may be useful if the best sections obtainable from a problem block are highly wrinkled. If sections are initially floated out on either cold or lukewarm water or 20% ethanol then transferred to the hot flotation bath on a slide, flat sections may be obtainable. 20% ethanol actively springs the wrinkles out because it has a lower surface tension than water.

Where blocks have been under-processed and contain residual solvent they tend to “explode” (rapidly disintegrate) on the water surface at normal flotation temperature. This effect may be reduced or avoided by using cold or tepid water for flotation .

## **Solution 5: Tape-transfer**

The Paraffin Tape-Transfer System is recommended for difficult-to-section tissues and Tissue Micro Arrays and provides an option for problem blocks. An adhesive tape window is applied to the cut surface of a block and rolled flat. A section is carefully cut and comes off the block attached to the tape. The section is applied to a special adhesive-coated slide, rolled flat and exposed to UV light to polymerize the adhesive. The slide is placed in solvent to remove the tape and stained normally<sup>23</sup>.

## Solution 6: Surface decalcification

Blocks are sometimes encountered that contain unexpected fragments of hard material. If this is calcium it can be removed from the surface of the block by surface decalcification. Foreign bodies such as sutures, staples, synthetic grafts etc, will not be removed by this technique and sometimes can only be dealt with by local removal from the block face.

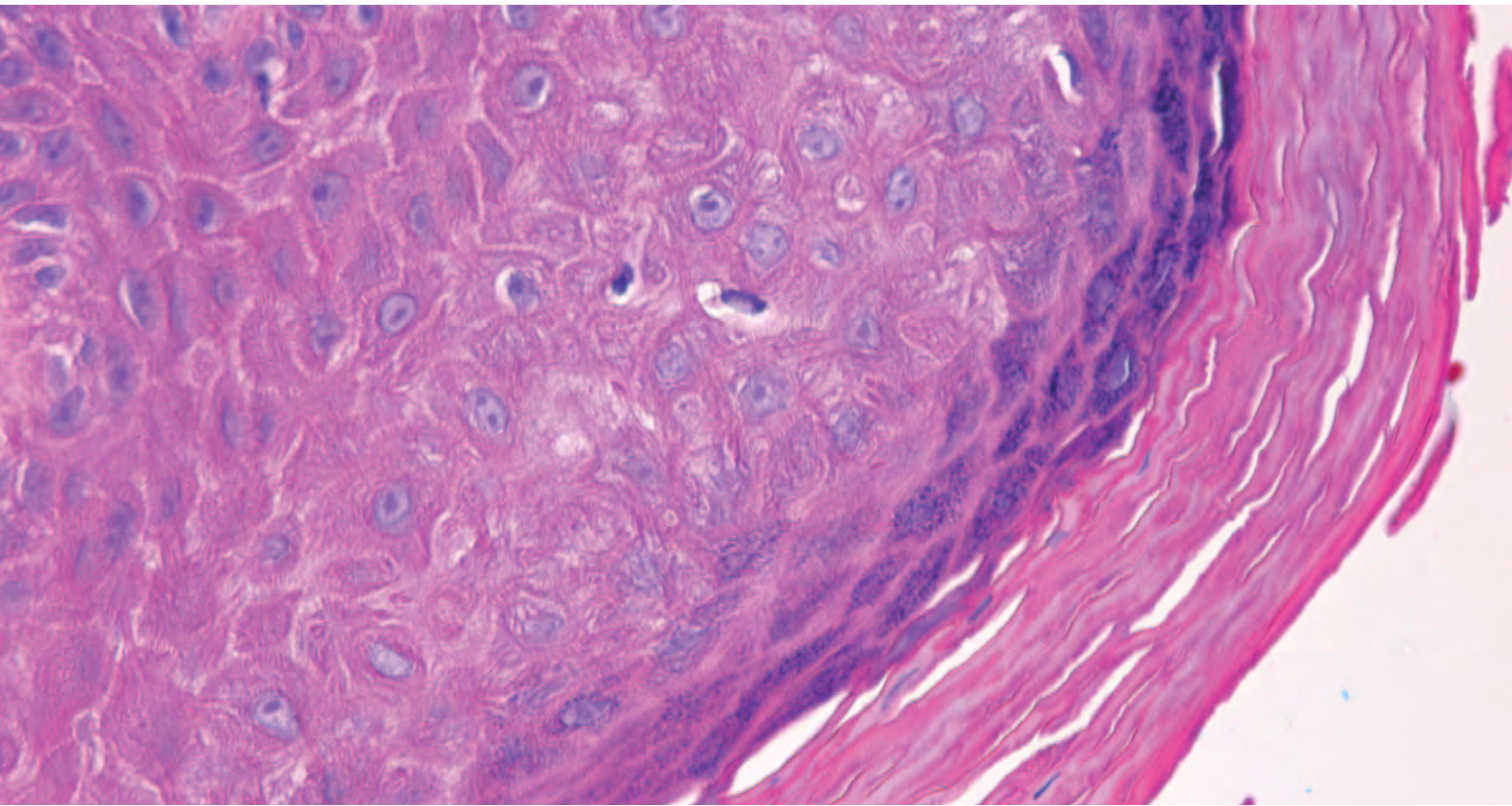
**Rationale:** Decalcifying agents will penetrate a small distance into the surface of exposed tissue in a paraffin block dissolving the calcium. This should allow several cohesive sections to be cut.

- » Soak the exposed block face in a decalcifying agent followed by thorough rinsing in water, chilling and recutting<sup>11</sup>. A thorough rinse is essential to avoid damage to the microtome blade-holder by the acidic decalcifying agent.
- » The time required will depend on the particular decalcifier used. Strong acid decalcifiers (such as those containing hydrochloric acid) should be applied for 5 to 15 minutes.
- » Strong acid decalcifiers can have an adverse effect on nuclear staining and should therefore be used conservatively.



## Caution:

It is not recommended to use acid decalcifiers to soften blocks that do not contain calcium as the acid reagent can have an adverse effect on subsequent staining. Figure 26 shows the epidermis in a section of skin treated with decalcifier in an effort to soften the keratin. Note the poorly stained nuclei in the superficial layers.



**Figure 26**

Skin section affected by acid decalcifier used to soften keratin

## Solutions involving reconstitution and reprocessing

### **Solution 7: For fixed tissue that has dried out completely and remains shrivelled and hard:**

Occasionally specimens can be “lost” during transport or at the grossing bench and dry out. This can also happen due to a processor malfunction, most often with “dip and dunk” tissue-transfer processors where the tissue might be exposed to air for an extended period following immersion in dehydrant or clearing agent.

Each of the following methods involves the use of a “reconstitution”, “restoration”, or softening agent. Some of these reagents have appeared in the paleohistology and paleopathology literature where they have been used for softening and rehydrating mummified tissues<sup>24-26</sup>.

### **Solution 7a: Specimens that have not been in wax**

**Rationale:** If the specimen has dried out after fixation but prior to processing (as can sometimes happen when a specimen is “lost” in the lid of a container or on the grossing bench) or during the early stages of processing, a “reconstitution” or “restoration” solution can be applied before processing to soften and rehydrate the tissue.

- » Place the specimen in a large volume of your chosen reconstitution solution (See Appendix Table 6) and leave for an appropriate time. Occasional gentle agitation may be useful. For small specimens one to two hours may be sufficient. For large specimens that have dried for an extended time 12 to 48 hours may be required.
- » Gentle palpation of the specimen may help you determine when softening is complete.
- » Process the specimen starting at an appropriate stage depending on the restoration agent used. If the agent is alcohol-based skip the formalin step and start with dehydration. Use a processing schedule that you initially would have considered suitable for the specimen.

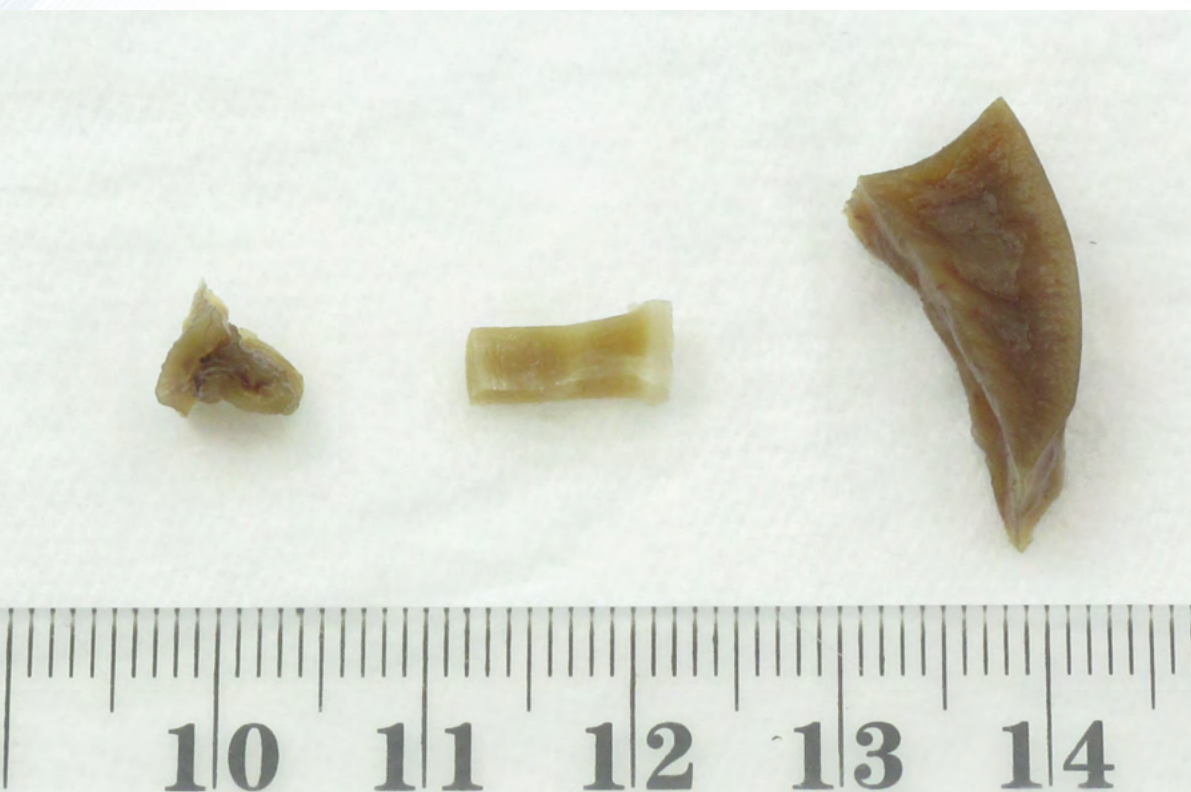The specimens shown in Figure 27A were dried out in a fume cupboard for one week following fixation. They were then reconstituted by immersion in neutral buffered formalin for 24 hours (Figure 27B). Note the swelling that has occurred as a result of rehydration.





**Figure 27A**

Specimens after drying



**Figure 27B**

Specimens after reconstitution

## Solution 7b: Specimens that have been processed to wax

**Rationale:** If the specimen has dried out during processing but has ended up in wax it will be necessary to remove the wax before using the reconstitution solution.

- » Using the cleaning cycle reagents, but preferably xylene not Waxsol, and avoiding any drying step, dissolve the wax and take the tissue back through alcohol to water<sup>14</sup>. Treat with a reconstitution solution such as sodium carbonate solution<sup>18</sup>, formol-glycerol<sup>15</sup>, or alcohol-glycerol<sup>10</sup> (see appendix Table 6), then reprocess starting at an appropriate stage and using a schedule that you initially would have considered suitable for the specimen.

## Solution 8: For dehydrated and cleared specimens with poor wax infiltration:

**Rationale:** On occasions specimens may be inadvertently removed from the processor wax bath before infiltration is complete or an inadequate infiltration time may have been used in a protocol. Providing dehydration and clearing are complete the following procedure may be used.

- » Place the cassettes back in the wax bath, melt them completely and give them at least two additional wax steps using vacuum for a period at least as long as would have been appropriate initially. Re-embed and section.

## **Solution 9: For properly fixed but incompletely processed specimens:**

Each of these methods involves using your tissue processor. It is very important that any problem with your instrument has been corrected and that any contaminated reagents have been replaced before reprocessing takes place. Reprocessing, if properly carried out, should allow cohesive sections to be obtained where previously this would not have been possible. The result however, will never be as good as that which would have been achieved if optimal processing had been applied in the first place.

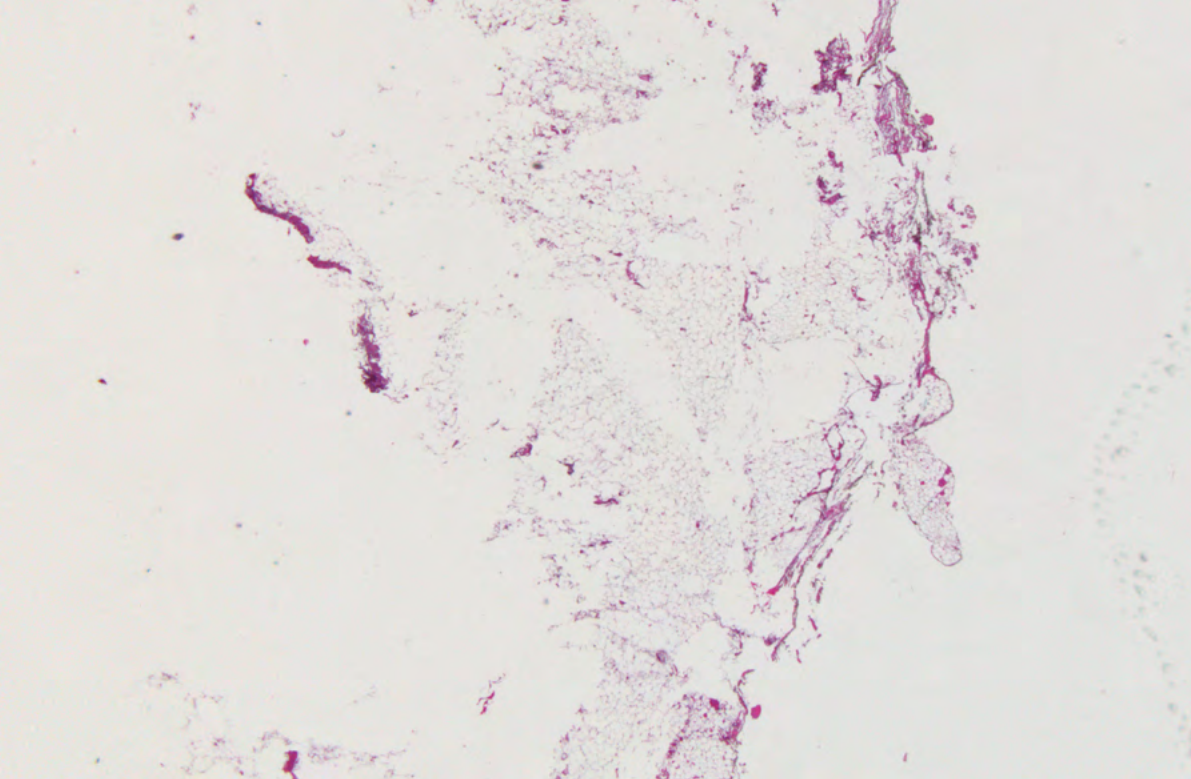


## Solution 9a: Reprocessing using saline (Taggart's method<sup>19</sup>)

**Rationale:** In this method excess wax is removed with hot saline prior to reprocessing. The saline gently rehydrates the tissue which is then processed normally. Saline is a non-toxic reagent that can safely be used in the open laboratory.

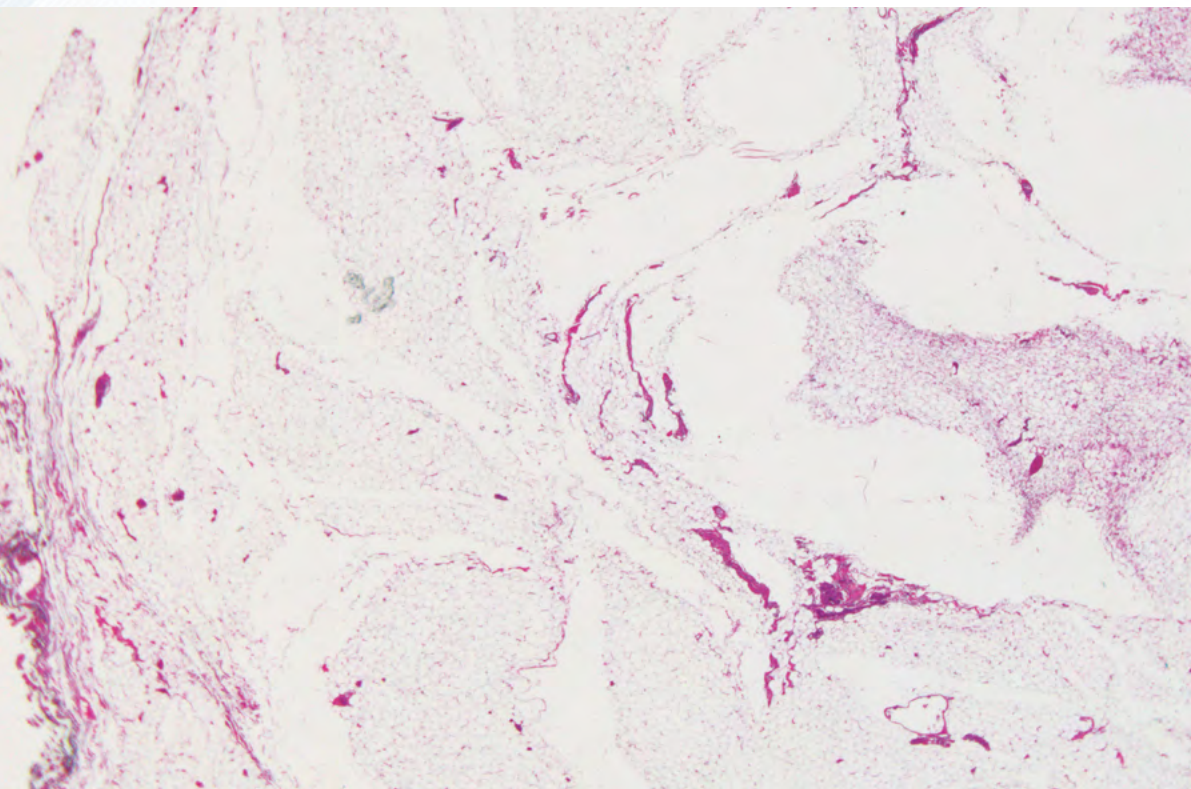
- » Before reprocessing melt down each block, gently blot off excess wax, and place specimens in a newly labelled cassette. This will improve access of the processing reagents to the specimens during reprocessing.
- » Place the cassettes in a beaker of isotonic saline (an aqueous solution of 0.9% sodium chloride) in an incubator at 65°C for one hour (one hour is sufficient for a range of specimen types and dimensions). This will melt the wax which will rise to the surface of the saline.
- » Remove the cassettes from the saline, drain briefly and place in your processor and reprocess from formalin using a schedule that would have been of appropriate length if used initially. This will depend on the size and nature of the specimen.

The micrographs in Figure 28 show what can be achieved with reprocessing using solution 9a (Taggart's method). This large specimen of subcutaneous fat would normally require an 8-hour schedule to be optimally processed. It was intentionally grossly under processed using a 2-hour cycle. Micrograph A shows the best section that could be obtained after this inadequate protocol. Micrograph B was taken after reprocessing using saline for wax removal and rehydration as described above followed by an 8-hour forward protocol then re-cutting the block. Although the section is now cohesive and of an acceptable standard a better result would have been achieved if the correct schedule had been used in the first place.



**Figure 28A**

Fat specimen before reprocessing



**Figure 28B**

Fat specimen after reprocessing



## Solution 9b: Reprocessing using the processor cleaning cycle or a modification thereof.<sup>13, 14</sup>

**Rationale:** This is a convenient method that uses the cleaning reagents to remove wax and take the tissue back to alcohol. It is a potentially harsher method than either 9a or 9c.

- » Before reprocessing melt down each block, gently blot off excess wax, and place specimens in a newly labelled cassette. This will improve access of the processing reagents to the specimens during reprocessing.
- » Place the cassettes into the tissue processor in a processing basket.
- » Run the processor clean (purge) cycle or a modification thereof, that uses the cleaning reagents (see Table 2). It is preferable to use xylene rather than Waxsol as it is slightly gentler in action. This will take the specimens back through xylene, and several changes of alcohol. It is important **not to let the tissue enter any drying phase** that might be part of the clean cycle (as is the case with the standard PELORIS “Quick Clean” protocol). The program would need to be aborted before this stage is reached. For this reason it is sensible to load a new protocol on your processor such as the one below.

**Table 2. Rapid reprocessing protocol for PELORIS rapid tissue processor using cleaning reagents**

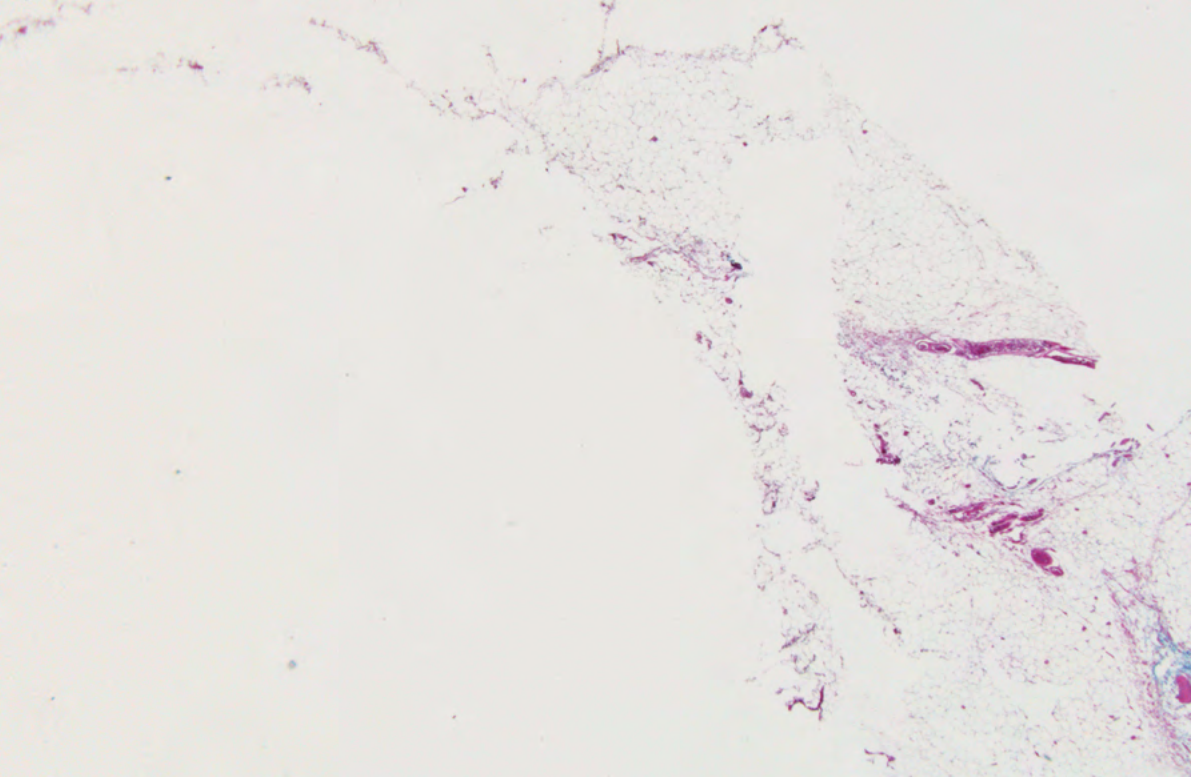
Step No.	Reagent Type	Time (min)	Temp (°C)	P/V	Stirrer	Drip Time (sec)
1	Cleaning solvent	12	65	Amb	High	10
2	Cleaning ethanol	6	55	Amb	High	10
	<b>Step time</b>	18:00				
	<b>Processing time</b>	22:00				

The specimens should now be in alcohol ready for reprocessing.

- » Reprocess from formalin or alcohol using a schedule that would have been of appropriate length if used initially. This will depend on the size and nature of the specimen. It might be convenient to hold your specimens in formalin and process with your next full specimen load.

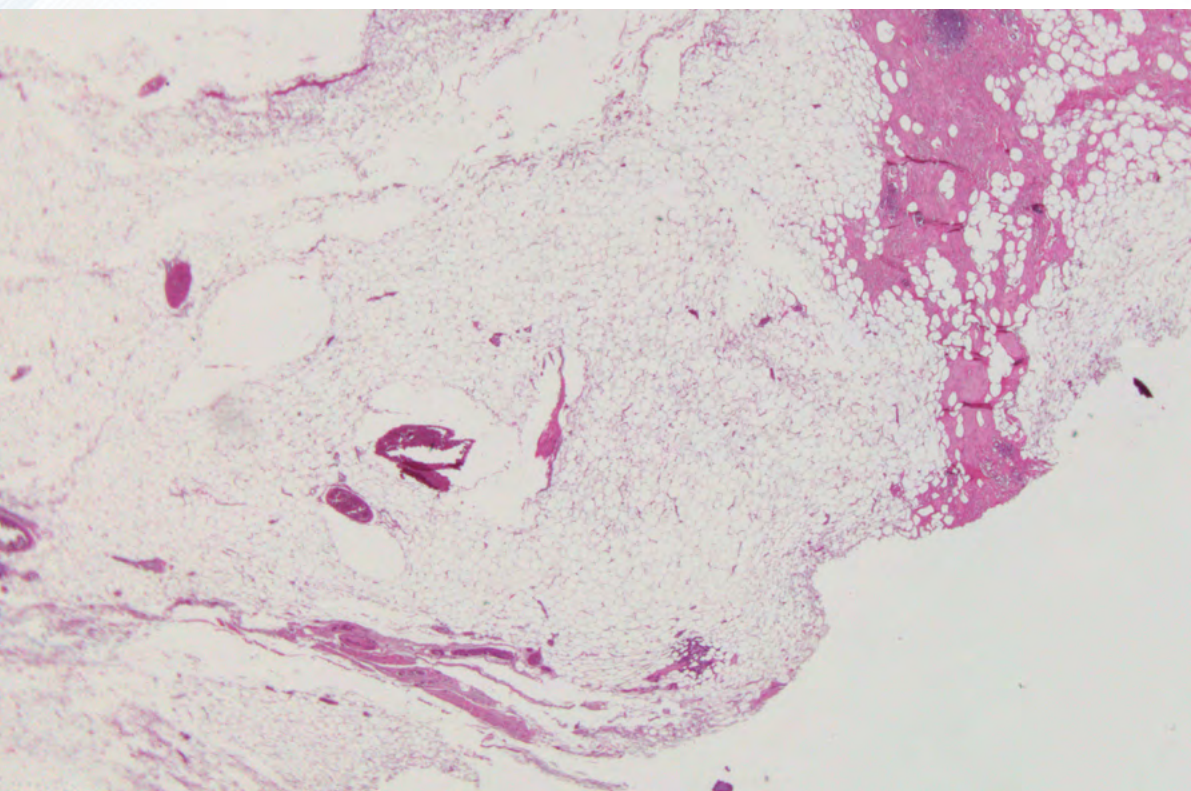
The micrographs in Figure 29 show what can be achieved with reprocessing using solution 9b (clean cycle reagents). This large specimen of subcutaneous fat would normally require an 8-hour schedule to be optimally processed. It was intentionally grossly under processed using a 2-hour cycle. Figure 29A shows the best section that could be obtained after this inadequate protocol. Figure 29B was taken after reprocessing using the short modified clean cycle (described above) followed by an 8-hour forward protocol then re-cutting the block. Although the section is now cohesive and of an acceptable standard a better result would have been achieved if the correct schedule had been used in the first place.





**Figure 29A**

Fat specimen before reprocessing



**Figure 29B**

Fat specimen after reprocessing

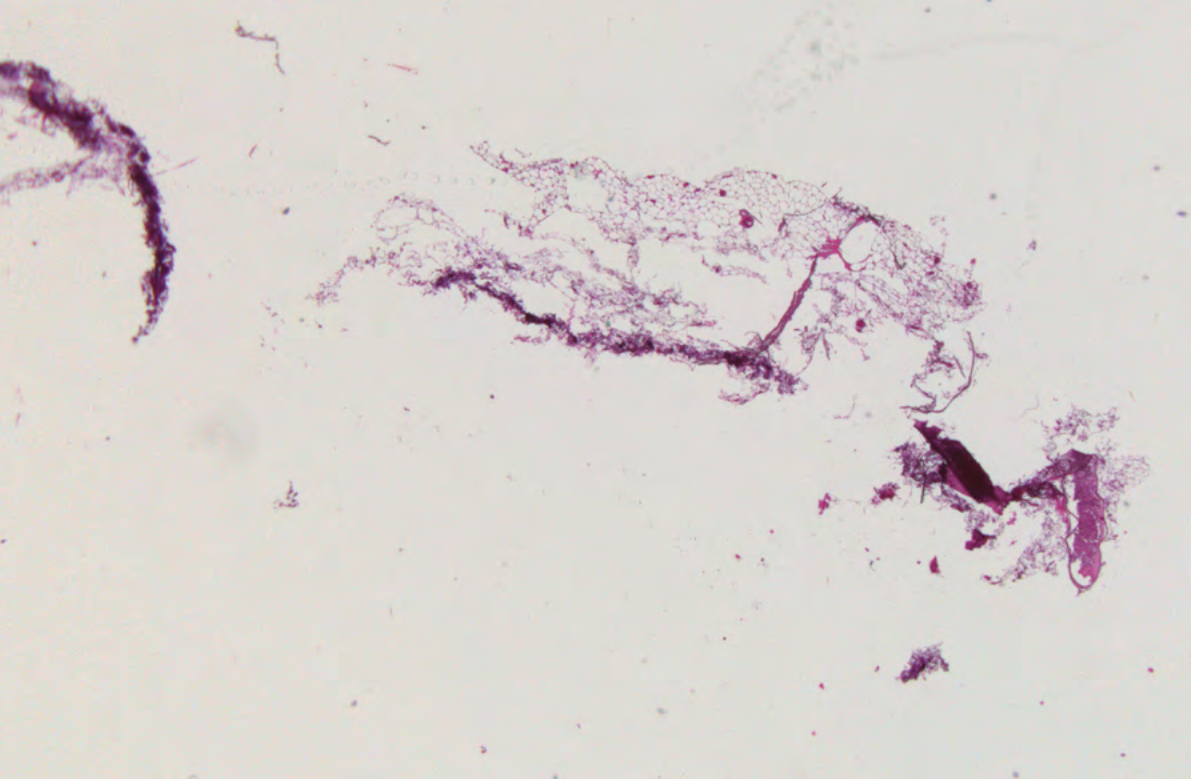
## Solution 9c: Direct reprocessing<sup>13</sup>

**Rationale:** This method does not require any pre-treatment prior to reprocessing. The parts of the specimen that were adequately processed initially receive little additional alcohol dehydration but additional clearing and wax infiltration is provided. Poorly processed areas receive additional fixation, dehydration, clearing and infiltration. A potential disadvantage of this technique is that it will cause some wax contamination of processor and processing reagents.

- » Before reprocessing melt down each block, gently blot off excess wax, and place specimens in a newly labelled cassette. This will improve access of the processing reagents to the specimens during reprocessing.
- » Place the cassettes into the tissue processor in a processing basket.
- » Reprocess from formalin or alcohol using a schedule that would have been of appropriate length if used initially. This will depend on the size and nature of the specimen. It might be convenient to hold your specimens in formalin and process with your next full specimen load.

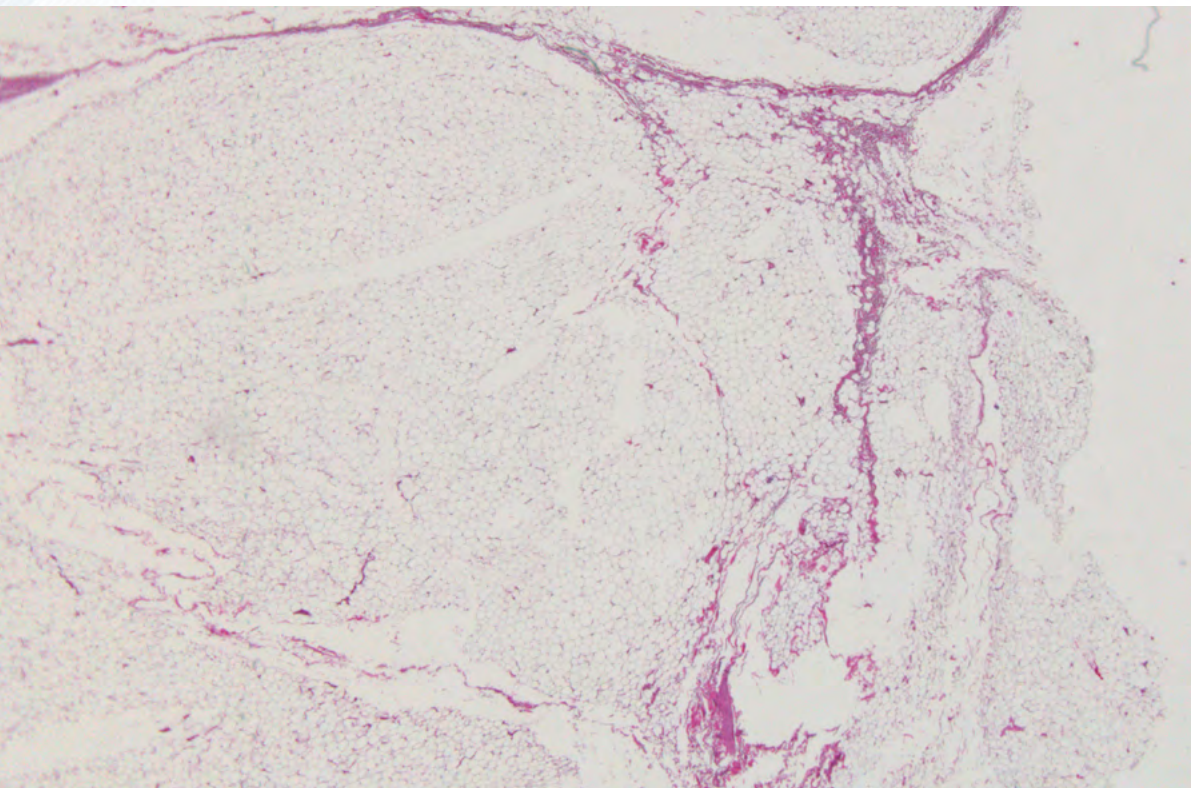
The micrographs in Figure 30 show what can be achieved with reprocessing using solution 9c (direct reprocessing). This large specimen of subcutaneous fat would normally require an 8-hour schedule to be optimally processed. It was intentionally grossly under processed using a 2-hour cycle. Figure 30A shows the best section that could be obtained after this inadequate protocol. Figure 30B was taken after direct reprocessing (described above) followed by an 8-hour forward protocol then re-cutting the block. Although the section is now cohesive and of an acceptable standard a better result would have been achieved if the correct schedule had been used in the first place.





**Figure 30A**

Fat specimen before reprocessing



**Figure 30B**

Fat specimen after reprocessing



## Solution 9d: Slow reverse processing

**Rationale:** This method of reprocessing takes longer than other methods but is probably the gentlest and most thorough of all the options presented. It involves taking the specimen slowly back through clearing agent to completely remove any wax, thoroughly removing the clearing agent with alcohol then completing re-hydration of the specimen. The specimen is then thoroughly forward processed using the schedule that would have been appropriate in the first place.

- » Before reprocessing melt down each block, gently blot off excess wax, and place specimens in a newly labelled cassette. This will improve access of the processing reagents to the specimens during reprocessing.
- » Place the cassettes into the tissue processor in a processing basket.
- » Run a modified reverse processing cycle such as the one shown in Table 3 below. This will take the specimens back through xylene or Waxsol, and several changes of alcohol. The schedule shown would be suitable for specimens of a size and nature that would normally process successfully in six to eight hours. The schedule should be scaled down (shortened) for smaller specimens.

**Table 3. Reverse processing protocol for PELORIS Tissue Processor**

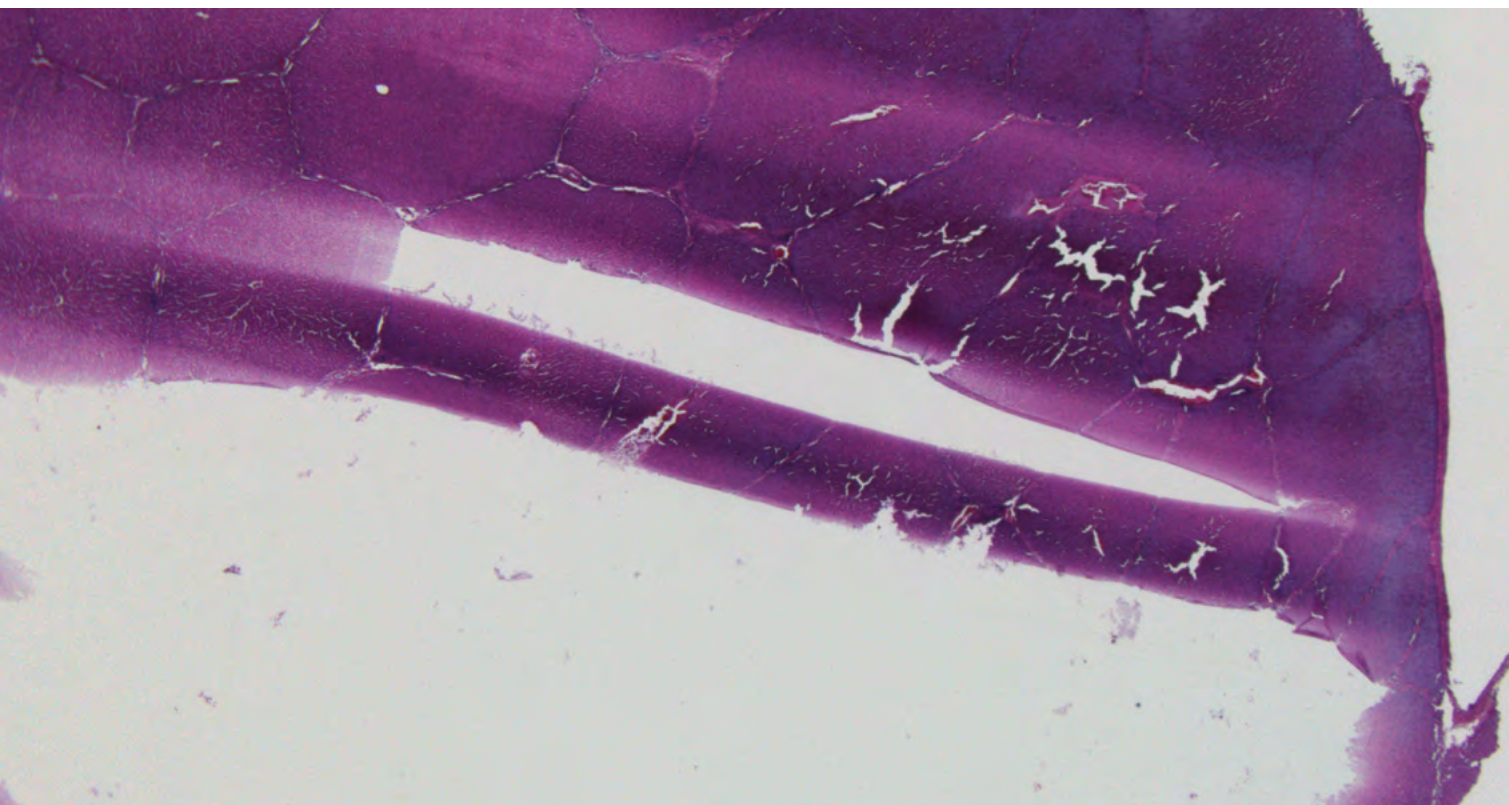
No.	Reagent Type	Time (min)	Temp (°C)	P/V	Stirrer	Drip Time (sec)
1	Cleaning solvent	60	Amb	Amb	High	10
2	Cleaning solvent	60	Amb	Amb	High	10
3	Cleaning ethanol	60	Amb	Amb	High	10
4	Cleaning ethanol	60	Amb	Amb	High	10
	<b>Step time</b>	240				
	<b>Processing time</b>	248				

The specimens are rinsed in 70% ethanol for 15 minutes prior to reprocessing.

- » Reprocess from formalin or alcohol using a schedule that would have been of appropriate length if used initially. This will depend on the size and nature of the specimen. It might be convenient to hold your specimens in formalin and process with your next full specimen load.

The micrographs in Figure 31 show what can be achieved with reprocessing using solution 9d (slow reverse processing). This large specimen of pig liver would normally require an 8-hour schedule to be optimally processed. It was intentionally grossly under processed using a 2-hour cycle. Figure 31A shows the best section that could be obtained after this inadequate protocol.

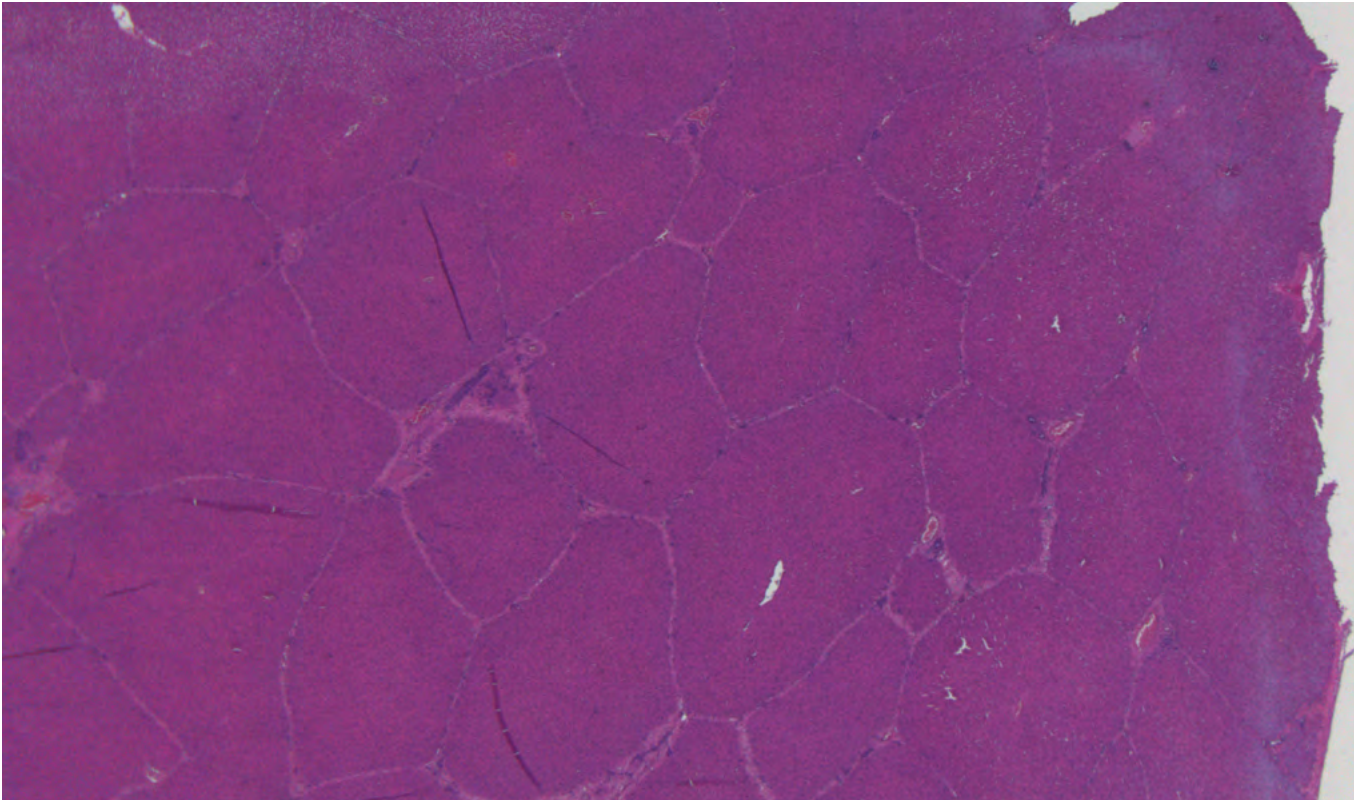
Figure 31B was taken after reprocessing using the reverse process shown in Table 3 above, followed by an 8-hour forward protocol then re-cutting the block. Although the section is now cohesive and of an acceptable standard some of the morphological damage produced by gross under-processing remains.



**Figure 31A**

Liver specimen before reprocessing





**Figure 31B**

Liver specimen after reprocessing

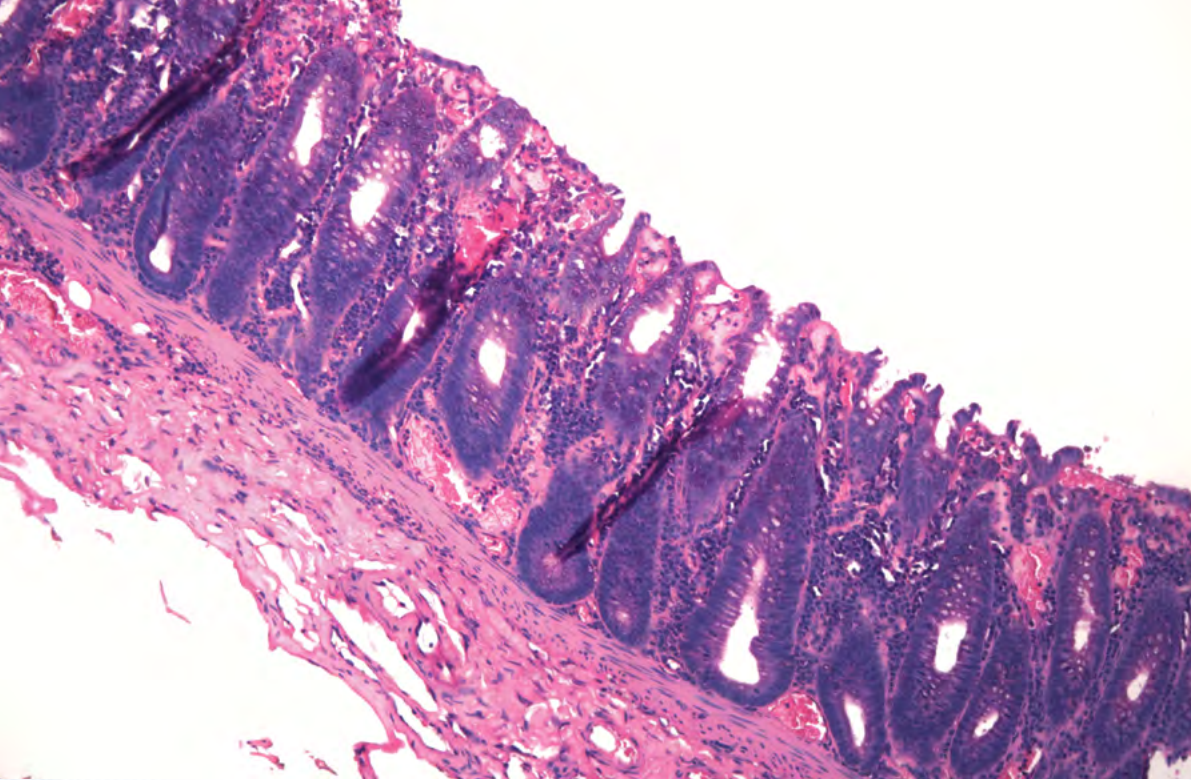
## Solution 9e: Slow reverse processing with reconstitution step

**Rationale:** This method takes longest of all but is of value in extreme cases where the staining has been badly affected by reagent contamination (such as contamination of specimens with formalin while in wax). Although it will not reverse the morphological damage that the original processing has produced, it will allow cohesive sections to be obtained and better H&E staining to be achieved. It is identical to method 9d above but it includes an additional step. After rehydration and prior to reprocessing the specimens are treated for 2 hours to overnight with a reconstitution agent such as BOND ER2 solution (epitope retrieval solution), Tris buffer at pH10.2, or more mildly with isotonic saline or 10% neutral buffered formalin. This will largely re-establish the normal eosinophilia of the tissue.

- » Proceed as in 9d above until the specimen is in 70% ethanol.
- » Place in a large volume of reconstitution solution at 65°C for 2 hours to overnight depending on the size and nature of the specimen. Small specimens should only require 2 hours at ambient temperature.
- » Reprocess from formalin or alcohol using a schedule that would have been of appropriate length if used initially.

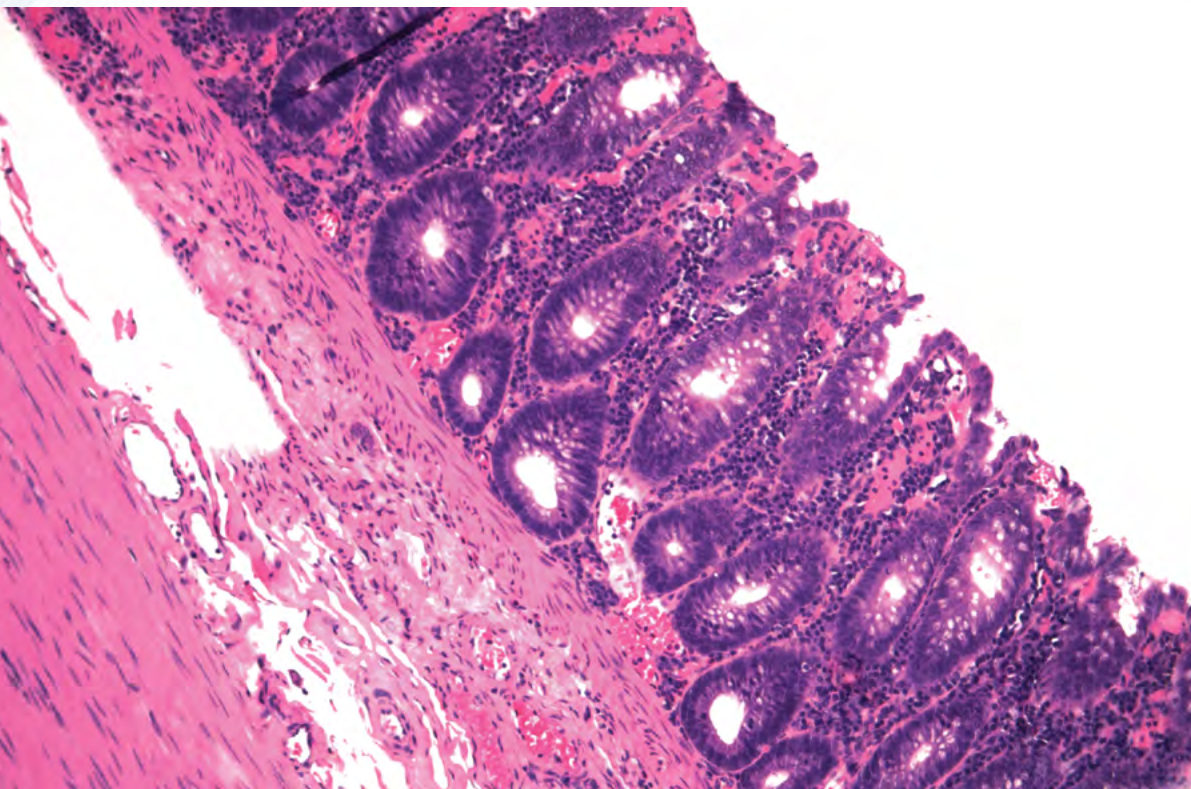
The artifact shown in Figure 32A was produced by intentionally contaminating a specimen with formalin just prior to infiltrating it with wax during what would normally be an adequate protocol. The “blue hue” and “nuclear meltdown” in this case are a direct consequence of the formalin contamination. This effect can be seen in grossly under-processed tissue or, on rare occasions, as a consequence of processor malfunction where formalin enters the retort during wax infiltration. Figure 32B was obtained after reprocessing the specimen using slow reverse processing combined with a reconstitution step (solution 9e using BOND Epitope Retrieval Solution 2 pH 9.0), then forward processing. Although the morphological damage remains, the quality of the section and the staining improved.





**Figure 32A**

Mucosal section with  
artefact caused by formalin  
contamination



**Figure 32B**

Mucosal section after  
reconstitution and  
reprocessing



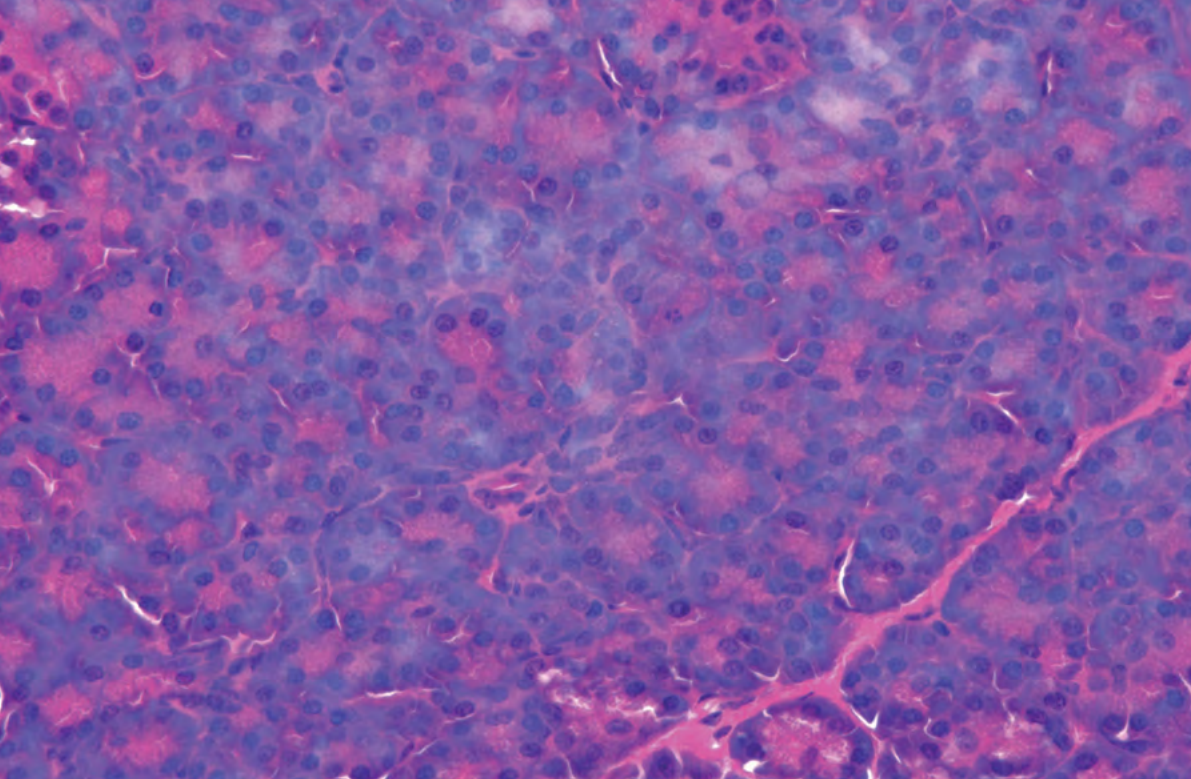
## Solution 10: For tissue that was poorly fixed and incompletely processed:

**Rationale:** Unfixed or poorly-fixed tissue will be damaged by tissue processing. The alcohol and high temperatures will exert a fixative effect of their own that will be different to that of formaldehyde. Unfixed tissue is poorly stabilized and more susceptible to hardening and shrinkage than properly fixed material. Poor fixation combined with under-processing therefore poses a major problem. Gentle reprocessing that includes some additional fixation is probably the best compromise. The following method is based on Taggart's method<sup>19</sup> which is one of the gentlest techniques of those we have described.

- » Before reprocessing melt down each block, gently blot off excess wax, and place specimens in a newly labelled cassette. This will improve access of the processing reagents to the specimens during reprocessing.
- » Place the cassettes in a beaker of isotonic saline (an aqueous solution of 0.9% sodium chloride) in an incubator at 65°C for one hour<sup>19</sup>. This will melt the wax which will rise to the surface of the saline.
- » Remove the cassettes from the saline and place in 10% neutral buffered formalin for an additional period. It should be remembered that the specimens may already be partially fixed with formalin and the alcohols used previously but additional formalin fixation may provide some benefit. This step could be carried out on your processor.
- » Reprocess from formalin using a schedule that would have been of appropriate length if used initially. This will depend on the size and nature of the specimen.

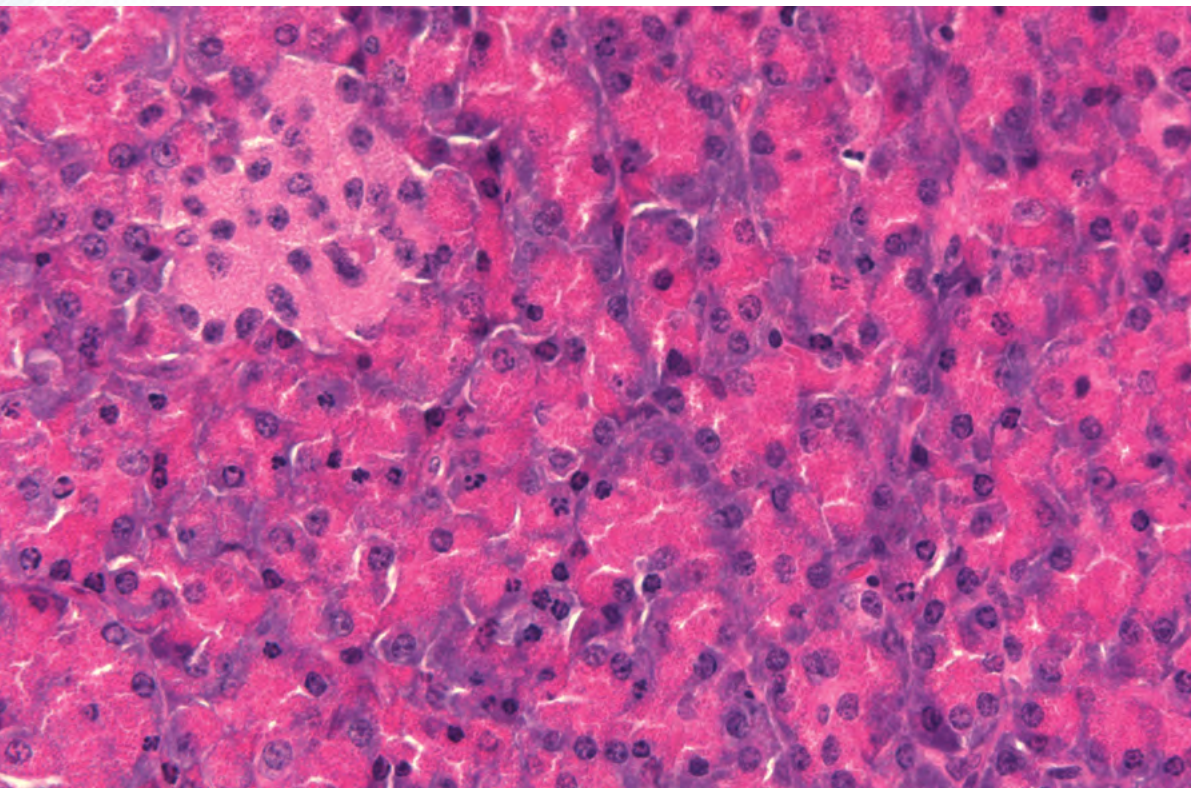
The artefact shown in Figure 33A was produced by intentionally under-fixing and grossly under-processing a specimen of pancreas. The block was very difficult to cut with a central area missing altogether. Intact areas of tissue showed very poor cellular morphology where the nuclei lacked detail ("nuclear meltdown") and had a bright blue hazy appearance ("blue hue"). Cytoplasmic texture was poor and cell margins poorly defined. The cells appear swollen.

Figure 33B was obtained from the specimen after reprocessing following the technique outlined in Solution 10 (Taggart's method with additional fixation). Although the morphology is better than that seen in the original sections and the "blue hue" has been partly removed, there remains some cracking and shrinkage present. The result is not as good as that which might have been achieved had adequate fixation and the correct schedule been used in the first place.



**Figure 33A**


Pancreas showing artefacts of under-fixation and under-processing



**Figure 33B**

Pancreas after reprocessing







## **Part 4**

### **Root Causes**

**The root cause of processing problems and their prevention**

## The root cause of processing problems and their prevention

A serious problem exists when laboratory staff are faced with a specimen or a batch of specimens from which satisfactory sections cannot be obtained. This may delay the histopathology report or, in the worst case, prevent a diagnosis being made at all.

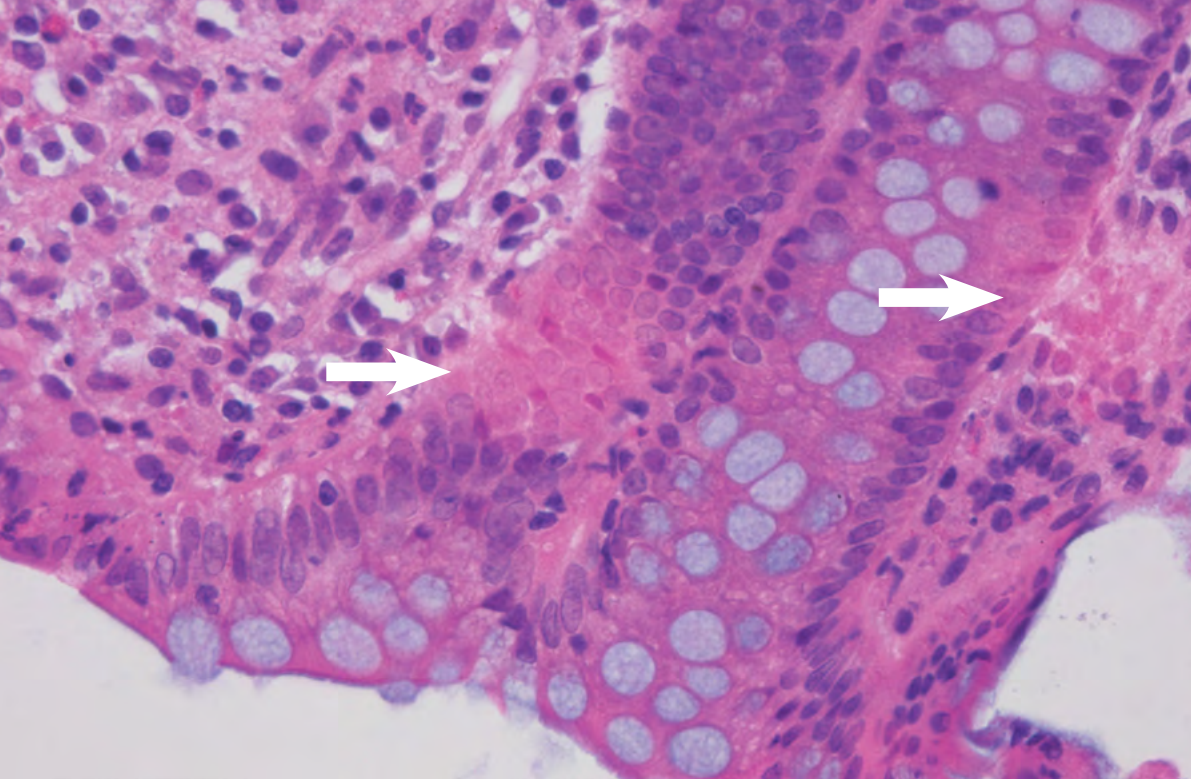
This situation produces considerable pressure to do something to remedy the problem and do it quickly. A short-term “fix” may involve using some “tricks of the trade” in order to get sections from a poorly processed block or, if this is unsuccessful, it may be necessary to reprocess the specimen.

Under these circumstances it is important to think very carefully to decide on the best course of action.

Sometimes, when a problem occurs, the first reaction of lab staff is to “blame the processor”. Certainly processors do malfunction at times but experience tells us that there are other occasions where the problem is a result of human error. Whatever the cause of the problem, a thorough, objective assessment must be made, avoiding any tendency to jump to an unjustified conclusion as to the cause.

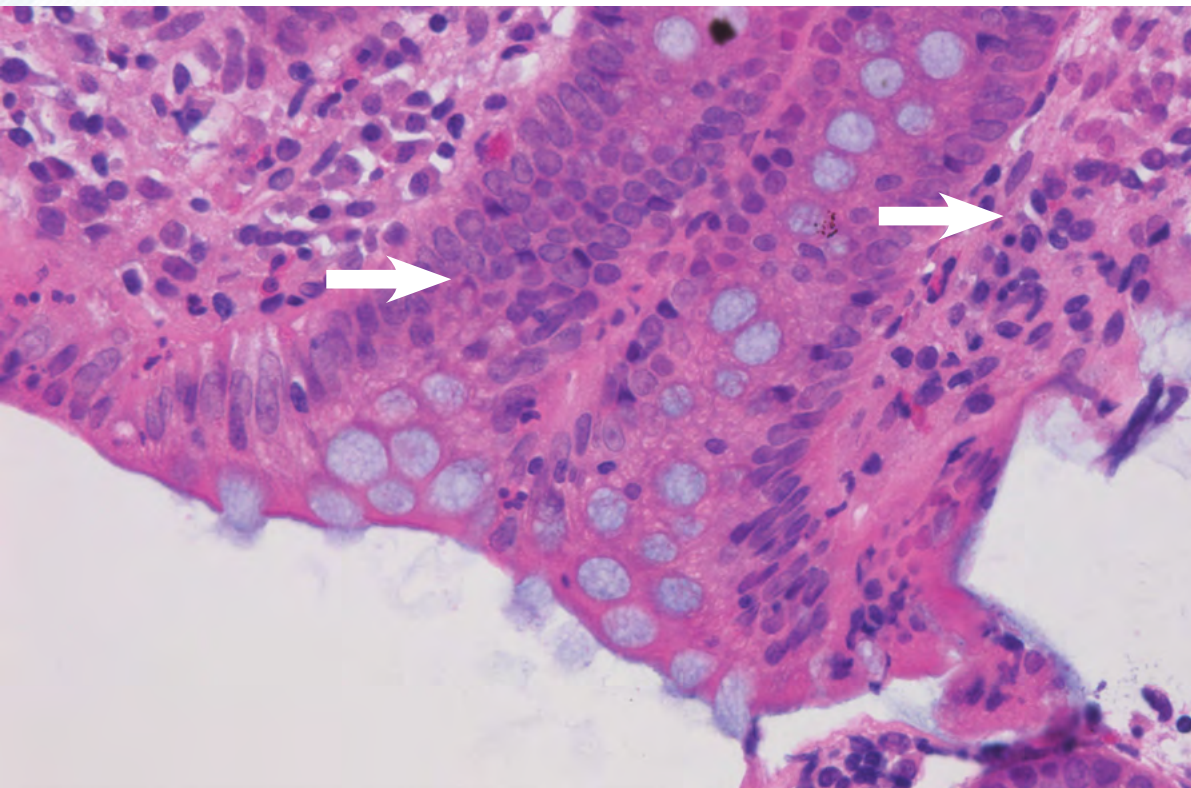
### Jumping to conclusions

In the example shown in Figure 34 laboratory staff sought help thinking they had a problem with their tissue processor. Several sections from a batch of endoscopic biopsies showed discrete areas with poor nuclear preservation and what appeared to be “nuclear meltdown”, indicated by arrows in Figure 34A. On careful examination of adjacent sections on the same slide (Figure 34B) it was determined that the problem was not processing but was caused by incomplete wax removal prior to staining, due to contaminated xylene on an automated stainer. In this case a more thorough assessment of the problem would have avoided considerable stress to staff. Refer to “nuclear meltdown” in Part 2 for a more complete discussion of this problem.



**Figure 34A**

Apparent processing artifact  
in endoscopic biopsy



**Figure 34B**

The same area in an adjacent  
section



## **Apart from solving the immediate problem facing a laboratory, it is essential to discover the cause and to make appropriate changes to avoid a recurrence.**

A timely investigation should be carried out. If you did not set the processor up or load it yourself you will need to talk to those who did while memories are fresh. If it is likely that the problem was caused by a fault in processor hardware or software, field support should be sought from the instrument supplier as soon as possible. If available, instrument logs can provide valuable information as to what went wrong.

The effects and some of the causes of poor processing are discussed in the following section.

### **The effects of poor processing**

Poor processing has both “macro” and “micro” effects on the specimen block.

#### **“Macro” effects include:**

Difficult section preparation

- » Block has poor texture (too hard, brittle, or soft)
- » Block is not uniform (interior different to exterior)
- » Block is not cohesive (components separate)
- » Sections compress (tissue not properly supported)
- » Ribbing poor (sections detach readily)

Difficult flotation and mounting

- » Sections sweat on the water bath (translucent or “wet” areas)
- » Components separate on water bath (may even “explode”)
- » Sections are impossible to flatten (even when the block is cold)

Block deteriorates on storage

- » Specimens shrink in block (due to evaporation of solvent)
- » Blocks contain opaque patches (due to the presence of water)

## **“Micro” effects include:**

Poor physical quality of sections

- » Sections are disrupted (large tears, areas missing)
- » Sections adhere poorly to slides
- » Sections are cracked (coarse and fine cracks, “parched earth”)
- » Sections are uneven in thickness (within one section)

Poor morphology (tissue preservation)

- » Poor nuclear detail (see Part 2 for a discussion of “nuclear meltdown”<sup>1</sup>)
- » Poor cytoplasmic detail
- » Some special features may be disrupted (eg. basement membranes)
- » Fibrous elements are poorly preserved (collagen, reticulin, elastin)
- » Preservation is not uniform throughout specimen (exterior versus interior)
- » Poor staining
- » Staining not uniform (across the section)
- » Nuclear staining is poor<sup>1</sup> (“nuclear meltdown” and/or “blue hue present” – see Part 2 for more information)
- » Cytoplasmic staining is poor
- » Extracellular components are poorly demonstrated

## The causes of poor processing

The most common causes of poor quality blocks are:

1. The tissue was not properly fixed before processing (fixation time too short, specimen too large, specimen not opened, etc.). Unfortunately, laboratory staff have limited control over the initial stages of fixation of surgical specimens. It is usually only after the specimens arrive in the lab that steps can be taken to optimise fixation. This is especially important with large specimens that need to be sliced or opened to allow access of fixative to tissue. After grossing specimens, additional fixation can be applied during the first step of processing. This can be very helpful. It should be remembered that tissue that is incompletely fixed by formalin initially, will be fixed by ethanol during processing. This can produce "zonal" fixation and unsatisfactory morphology.
2. The specimens are too thick for the protocol selected. This can be a problem when inexperienced personnel are grossing specimens, particularly with dense tissues such as uterus. During the time programmed for processing stages, solvents do not have long enough to penetrate to the centre of the specimen meaning that wax infiltration will not be complete and the block will not section. Best results are obtained from tissue slices between 3 and 4 mm thick.
3. The tissue is too dense for the protocol selected. Some tissues are penetrated very slowly by fixatives and processing reagents due to their density. Fibro-muscular tissue, decalcified bone and cartilage, keratin and nail or chitin are all examples of dense tissues and, even when sliced thinly, may take longer to penetrate than most other tissues.
4. The tissue is too fatty for the protocol selected. Large breast specimens or skin excisions containing large areas of subcutaneous fat require longer protocols because fat is a barrier to dehydration and, if water remains in the specimen, leads to incomplete clearing and wax infiltration and poor tissue support. Ethanol is a poor fat solvent, isopropanol is better. Additional time is required for both dehydration and clearing in protocols to be used for fatty specimens.
5. The tissue contains calcium deposits that have not been removed by prior decalcification, or foreign bodies, sutures, staples, synthetic grafts etc. The problem here is that calcium deposits and most foreign bodies will not be penetrated by processing reagents no matter how long the step times and will therefore be unsupported by wax and will not section. Small amounts of calcium can be removed by surface decalcification (see Solution 6) but if large amounts are present reverse processing back to water followed by normal decalcification might be required. This might be the case if bone that had not been decalcified was inadvertently included in a normal processing run. For other foreign bodies it may be necessary to physically remove them from the specimen prior to processing or from the block face to allow sections to be obtained (after consultation with your pathologist).
6. The schedule was too short so specimens were:
  - » Not properly fixed
  - » Or not properly dehydrated
  - » Or not properly cleared
  - » Or not fully infiltrated with wax
  - » Or a combination of the above.



This problem is most often seen when a mixture of small and large specimens are processed in the same batch. Whilst the schedule may suit the majority of the specimens the very largest or densest may not be fully processed. It tends to happen when shorter schedules are introduced in an effort to reduce turnaround times without appropriately restricting specimen dimensions or the types of specimens processed on the shorter runs. Refer to “Compromises in processing” below for a further explanation.

7. The schedule was too long so delicate or tiny specimens were:
  - » Exposed to dehydrants for too long
  - » Or exposed to high concentration dehydrants too soon (especially poorly fixed tissue)
  - » Or exposed to clearing agents for too long
  - » Or exposed to hot wax for too long
  - » Or exposed to high temperatures for too long
  - » Or a combination of the above.

Over-processing is a common problem in small specimens containing particular tissue types such as glandular epithelial tissue (as in endoscopic biopsies) and hematopoietic and lymphoid tissues. As in 6 above, this problem is most often seen when a mixture of small and large specimens are processed in the same batch. The over-processed specimens become brittle and can be very difficult to section. Refer to “Compromises in processing” below for a further explanation.

8. The schedule was incorrectly proportioned for the specimen types being processed (e.g. rodent tissues typically require a different ratio of step durations compared to human tissues). The total duration may appear satisfactory but the time in particular stages may be inappropriate. Some examples are:
  - » Insufficient dehydration before clearing. This will mean the specimen still contains water and will not clear or infiltrate no matter how long it is left in clearing agent or wax.
  - » Excessive dehydration before clearing can result in over-dehydration by removal of bound (molecular) water from the specimen. In susceptible tissues, such as mucosal tissue from the gut, this can result in very brittle blocks<sup>27</sup>.
  - » Insufficient clearing before wax impregnation may mean that the tissue will not be properly infiltrated with wax due to remaining alcohol and therefore not properly supported in the block.

- » Excessive clearing before wax impregnation can produce brittle tissues. Again it is delicate epithelial tissues that are most likely to be affected.
- » Insufficient time in wax will mean that clearing agent will not be fully displaced by wax within the specimen. Wax mixed with clearing agent will not properly harden to support the tissue and sections will be difficult or impossible to obtain. After sectioning and during storage, the face of blocks that still contain clearing agent will contract due to evaporation of the solvent.
- » Excessive time in wax can cause excessive hardness, brittleness and shrinkage in susceptible specimens.

Standard recommended protocols for the PELORIS tissue processor, ranging from one to twelve hours duration, employ the following proportions of total step time for dehydration, clearing and wax infiltration (refer to table 4). These protocols have been validated by extensive testing and recommended protocols for other processors follow a similar pattern. The step time for fixation is not included in the calculations as it will vary considerably from laboratory to laboratory depending on their particular requirements.

9. A problem with programming or loading the processor such as:

- » The wrong schedule chosen from those available. This is a common reason for reprocessing specimens and is due to human error. Large specimens processed on a rapid two hour programme instead of an eight hour schedule will be substantially under-processed. Reprocessing would be necessary. Tiny specimens normally processed with a two hour schedule will be shrunken and brittle if processed over eight to twelve hours. In this case all that can be done is to use a range of “tricks of the trade” to get sections if possible.
- » Baskets over-loaded with cassettes. This is most likely to occur when cassettes are placed randomly in baskets without racks and are not completely covered by processing reagents during processing. Usually only a few cassettes at the very top of the basket are affected. Incorrect fill levels in the processor retort can produce a similar effect. The effect on tissues will depend on

**Table 4. Major processing steps as a proportion of total step time (excluding fixation)**

Stage	Reagent	Proportion(+/- 5%)
<b>Ethanol/Xylene protocols</b>		
Dehydration	Includes graded and absolute alcohols	40%
Clearing	Xylene	30%
Infiltration	Wax	30%
<b>Xylene-free protocols</b>		
Dehydration	Includes graded ethanol and ethanol/isopropanol mixtures	35%
Clearing	Isopropanol	30%
Infiltration	Wax	35%

which reagents have not made contact with specimens.

- » Cassettes over-loaded with tissue. This can be a common problem in some laboratories usually due to the inexperience of a staff member grossing specimens. Fluid circulation within cassettes crammed with tissue is restricted and poor processing will result. In addition localised pressure effects caused by protruding parts of the cassette lid can compromise the morphology in parts of the tissue.
- » Inappropriate cassettes used. The design of cassettes is important and influences the quality of processing. It is essential that the cassette safely encloses all the tissue, including small fragments, and allows unrestricted access of processing reagents. As there are many different cassette suppliers in the market, cassettes should be carefully chosen with this in mind. Fine mesh cassettes, tissue wraps or foam biopsy pads are commonly used for small specimens and each, in their own way, will restrict fluid flow and slightly increase the amount of fluid carryover from one reagent to the next. Allowance must be made for this in choosing a suitable processing schedule and compensating for the increased carryover when replacing processing reagents.

10. A problem with processor maintenance such as:

- » Inadequate training of staff. It is vital that all staff who are operating processors and dealing with routine maintenance are fully trained and understand the reasons why particular procedures are carried out and the consequences of departing from them.
- » Using an incorrect reagent when replacing solvents. For example if 70% ethanol was mistakenly used to replenish a container that should contain absolute ethanol your processor may use that reagent as a final dehydration step. This would mean that dehydration would not be complete and the resultant processing would be incomplete. This problem can be difficult to identify.
- » Replacing solvent containers in the wrong order. This can produce similar results to those described above. It is important to remember that even though a container may be filled with the correct reagent and accurately labelled, if it is not in the correct location in the processor the instrument will not detect this and faulty processing may result.
- » Using heavily contaminated reagents that should have been replaced (ignoring threshold warnings). Each time a specimen load is processed, the processing reagents are contaminated by tissue fluid, lipid and fixative that leach out from the specimens. Reagents are also carried over by the specimens themselves, cassettes, cassette baskets, biopsy pads and wraps, and components of the retort itself each time the retort is drained and refilled. It is essential to have a well-established regime for



replacing contaminated processing reagents. Use of contaminated reagents can lead to incomplete dehydration, clearing or infiltration and result in faulty processing. Manufacturers of processors make recommendations as to when reagents should be replaced based on the number of baskets processed, the number of cassettes processed, the proportion of cassettes containing biopsy pads etc. These recommendations, combined with the experience of staff should lead to the establishment of strict procedures that should be closely followed.

- » Using recycled reagents of unsatisfactory quality. The quality of processing reagents is important. There is a limit to the extent to which some reagents can be recycled and it is necessary to introduce fresh reagent regularly. The instructions provided by the suppliers of commercial recyclers should be closely followed.
- » Starting the purge (cleaning) cycle before removing specimens. If a basket of cassettes is inadvertently left in the processor retort and the wax is drained and a purge (cleaning) cycle commenced the specimens will be immersed in a hot de-waxing agent and may potentially go through alcohol and a drying step depending on when the mistake is detected. Reprocessing will be necessary and careful thought must be given as to what is the best starting point and how re-processing will be achieved.

11. A processor malfunction that resulted in:

- » A failure to fill leaving specimens in air for a prolonged period, allowing drying to occur. A failure to fill combined with retort heating could cause a problem but in most fluid-transfer processors specimens take considerable time to dry inside a sealed chamber. Specimen drying is a much more likely problem with older tissue-transfer ("dip and dunk") machines.
- » Specimens being immersed in a particular reagent for an excessive time (such as absolute ethanol, xylene or wax). This can have serious consequences, particularly with small delicate specimens, resulting in over-processed, extremely brittle blocks. It is particularly serious when hot reagents are involved.
- » Specimens being subjected to excessive heat. This is an unlikely event because modern processors are equipped with safety thermostats that should protect against over-heating. If specimens are exposed to very high temperatures they can be irreparably damaged.

- » Specimens being placed in contaminated reagents (such as wax contaminated with formalin). There are reports of faulty valves causing contamination of wax and clearing agents.<sup>21</sup> The consequences of formalin contamination are demonstrated in solution 9e (Part 3). Contamination of clearing agents (xylene and isopropanol) and wax have the most serious consequences. Reprocessing can produce cuttable blocks from specimens compromised by contaminated reagents but some morphological damage will remain.

## Compromises in processing

### **Can I process small and large specimens in the same processing run and expect to get optimal results? What is the effect of the total length of a processing schedule on processing quality?**

The graph shown in Figure 35 demonstrates the compromise that occurs when a processing run contains a mixture of very small and very large specimens. It represents the hypothetical processing of three very different specimens. The results shown are based on the experience of the writer and some laboratory testing. It is the underlying principle that is important here, not the specific results.

The “arbitrary quality scale” represents the overall processing quality that is achievable when a particular specimen is processed

using a schedule of a specific total duration (“processing time in hours”). In this model we have assumed the tissue is properly fixed and the processing schedules are properly proportioned. We have included a range of processing schedules with durations ranging from one to twelve hours. “Processing quality” is represented by a score between one and one hundred calculated by looking at all the “macro” and “micro” effects of poor processing<sup>28</sup> described on Page 70 and 71. The yellow line, shown at a score of 50, represents the point at which processing becomes just acceptable. A score of 80 – 90 represents high quality processing.

Very different specimens have been chosen to illustrate the problem. A 2 mm endoscopic biopsy that is tiny and fragile, might give best results when processed using schedules between one and three hours in duration, whereas a 3 mm thick specimen of myocardium might give best results at durations between four and seven hours. A 5 mm thick wedge of cervix, which is very dense fibro-muscular tissue might require processing from eight to twelve hours to get good results.

The graph shows that a 3.5 hour schedule would produce acceptable results if the endoscopic biopsy and the myocardium specimens were processed in the same run, while a 7.5 hour schedule would produce acceptable results if myocardium and cervix were processed together. This model also suggests that it would not be possible to find a compromise schedule that would produce acceptable processing if the endoscopic biopsy and the cervix specimens were processed in the same run.

Bear in mind that this is a hypothetical model. Different processors and different processing reagents would produce curves that differed in detail, but the problem of a “one size fits all” approach to tissue processing is clearly shown. It is not possible to process very small, delicate specimens and large robust specimens using the same processing schedule and get optimal results for both.



Processing quality as a function of schedule duration

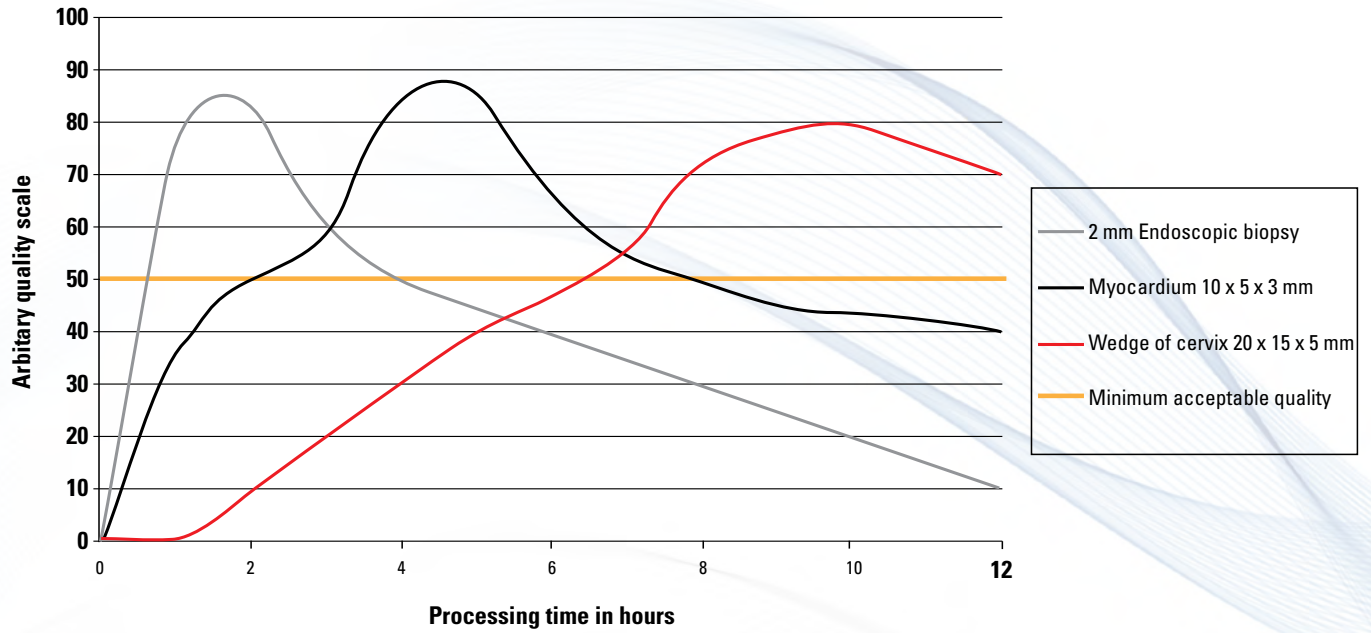



Figure 35




## **Part 5**

# **Validation**

## **How to validate a reprocessing method**






## How to validate a reprocessing method

The suggestions included in this publication are general in nature and based on limited testing and field experience. It is recommended that every laboratory validate reprocessing methods for themselves under the conditions and with the equipment that applies in their laboratory. It is very helpful to have a proven method available if the need arises to reprocess tissues.

Suggested procedure for validation:

The following method was used to test the reprocessing methods described in this publication. It is straightforward and could be employed by any laboratory wanting to validate a method for their own use.

1. Choose several specimen types for testing. These should be challenging tissues that you have found by experience to be the most likely to be affected by poor processing. Good examples are large specimens of fatty breast tissue or wedges of cervix. The tissue would need to be obtained from non-diagnostic specimens of surplus tissue. For results to be reproducible and comparable testing is best applied to thoroughly fixed tissue.
2. Decide on a processing schedule that you would normally use for the specimen types you have chosen and prepare tissue blocks of precise dimensions that you are confident would be adequately processed by that protocol. For example you might prepare blocks of cervix measuring 15 x 10 x 4 mm, that you would normally process on an eight-hour cycle.
3. Substantially under-process your specimens using a cycle that you know to be too short and embed them in the normal way. For example, you might process the cervix blocks described above using a two-hour cycle.
4. Confirm that your specimens are unsatisfactory by exposing the tissue in the block and attempting to obtain cohesive sections.
5. Apply the reprocessing method that you wish to validate. As a starting point for the forward processing (final) part of the reprocessing method, use a schedule of the same duration as the one you would normally use for specimens of that type and size. For example for the cervix specimens described above you would reverse process them using your chosen method to dewax and re-hydrate them, then forward process on an eight-hour cycle for the final stage of reprocessing.
6. Re-cut your blocks to confirm that reprocessing has been successful.
7. Stain sections using a range of methods to determine whether severe under-processing followed by reprocessing has adversely affected staining. IHC and ISH should be considered particularly when using reconstitution steps.
8. If appropriate write up your method as a standard operating procedure.





## **Part 6**

## **Appendix**

## Reprocessing Decision Trees

As there are so many possible causes of poor quality blocks, a logical process must be followed when deciding the best course of action. Three decision trees are provided.

Decision tree 1 deals with specimens that were inadequately treated before they were processed. It covers poorly-fixed specimens and those containing calcified areas, not removed by appropriate decalcification. The unlikely situation where specimens completely dry out before or during processing is dealt with in decision tree 3.

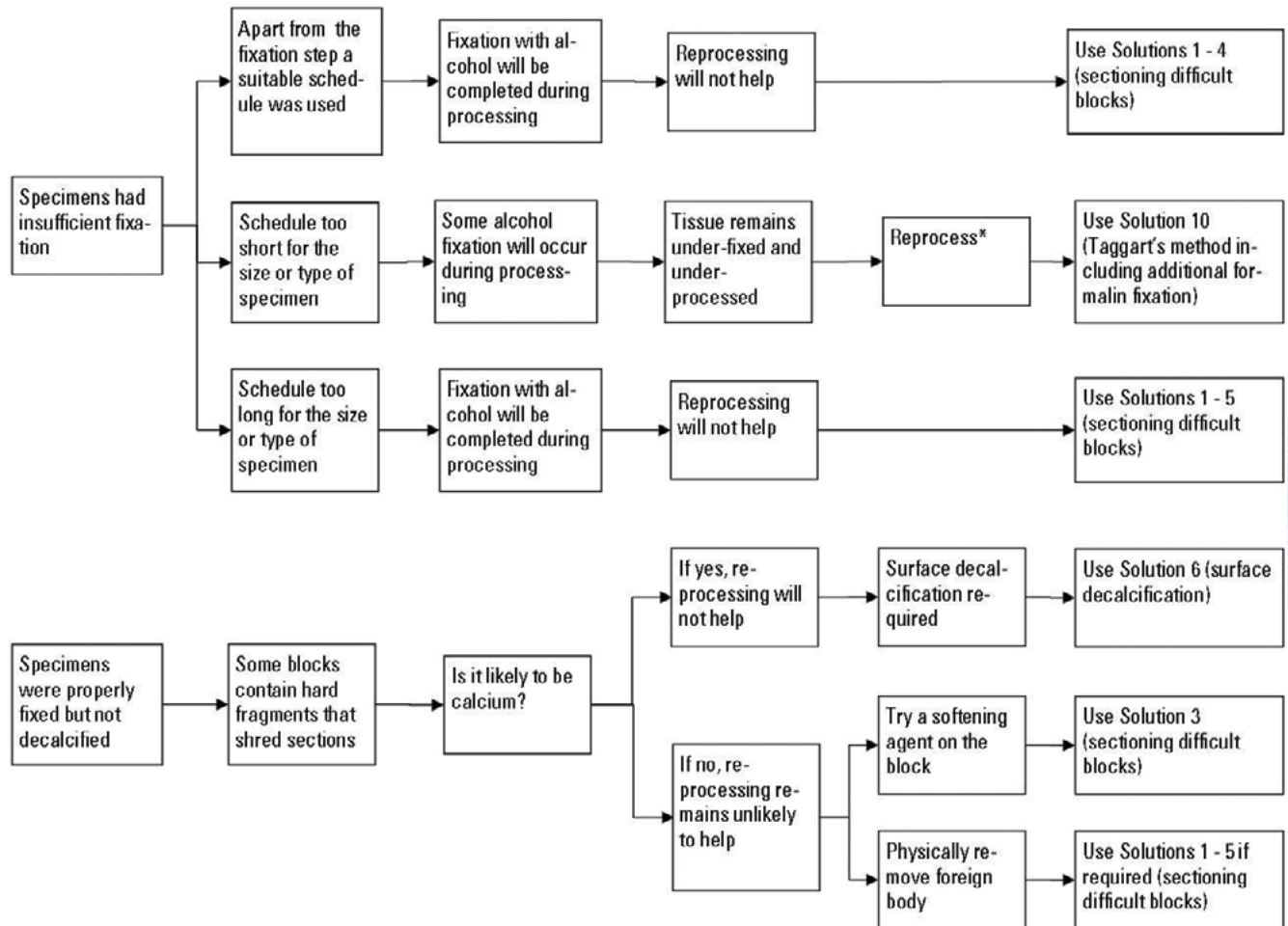
Decision tree 2 covers the situation where there was nothing wrong with the processor or processing reagents but an inappropriate schedule was used to process specimens.

Decision tree 3 deals with processor malfunctions and reagent problems.

### **WARNING:**

The decision to reprocess tissues should only be made after very careful consideration because, in some situations, reprocessing can make the situation worse - not better.

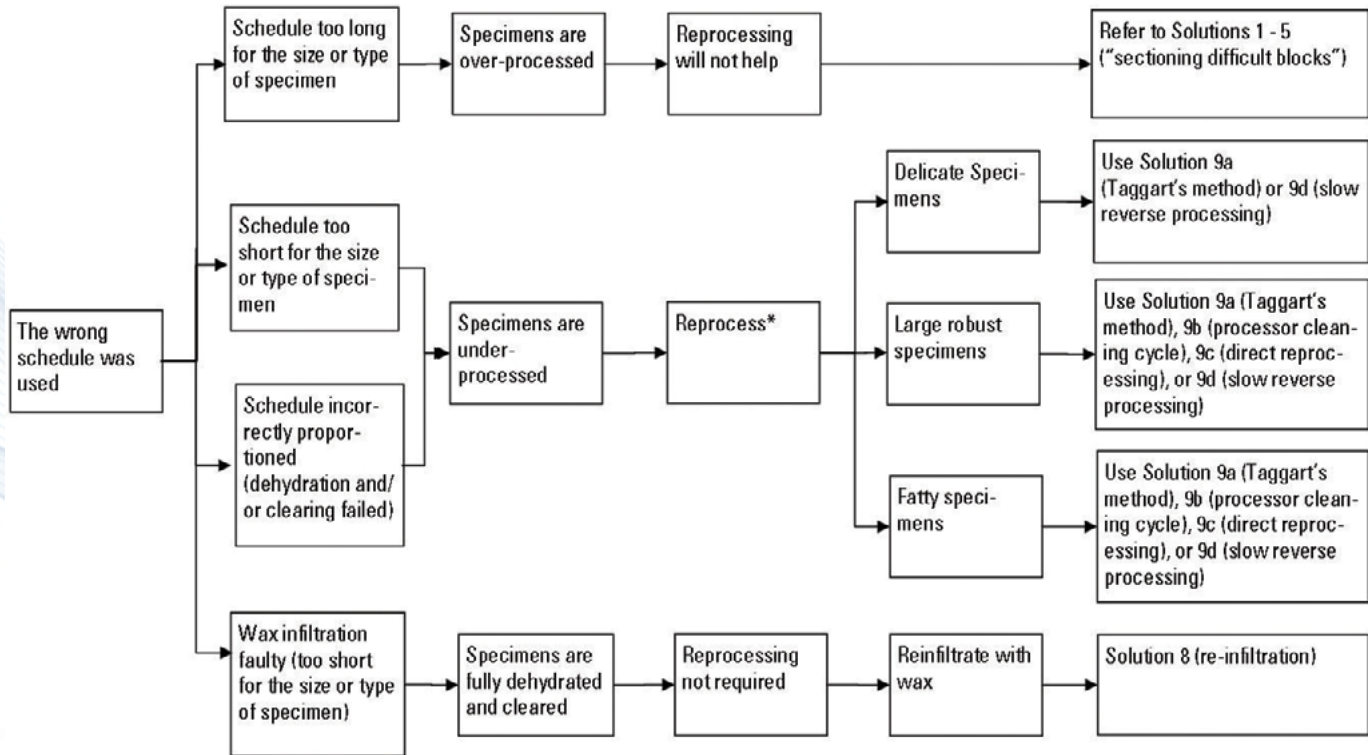
## Decision Tree 1: Inadequate Fixation or Decalcification



\* Remember to replace any contaminated processing solutions on your processor before using it for reprocessing

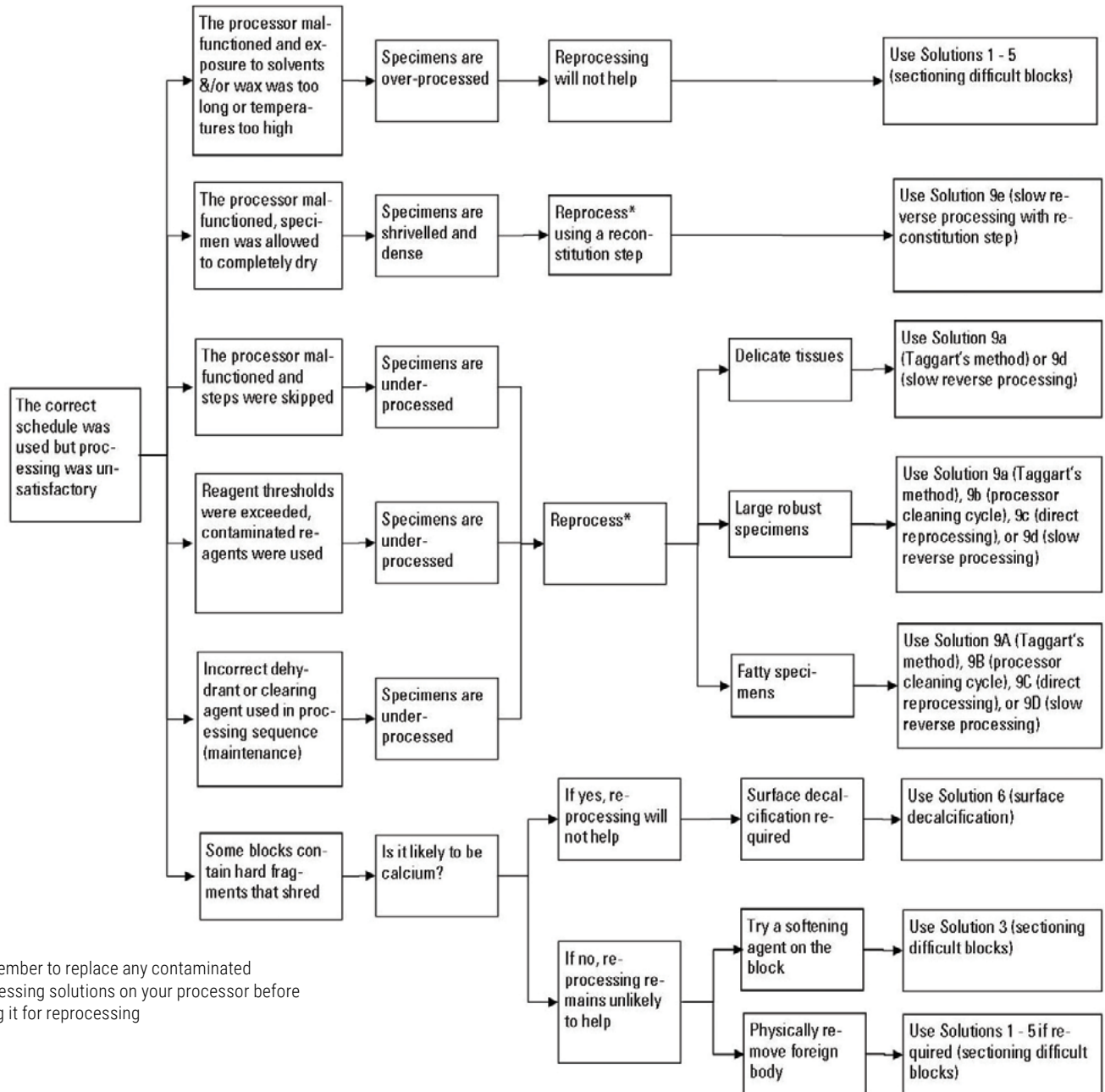


## Decision Tree 2: Wrong Schedule Used



\* Remember to replace any contaminated processing solutions on your processor before using it for reprocessing

## Decision Tree 3: Processor or Reagent Problems



\* Remember to replace any contaminated processing solutions on your processor before using it for reprocessing

**Table 5. Softening fluids for use on the block face**

Method	Composition	Application	Reference
Ice water	Clean water	Place the trimmed block surface on melting ice or in a tray of ice water at 4°C for a few minutes and recut.	Anderson <sup>10</sup> Carson <sup>27</sup> Culling <sup>21</sup> Drury & Wallington <sup>6</sup>
Baker	60% Ethanol 90 ml Glycerol 10 ml	Place the trimmed block surface in solution for a few minutes, rinse in water, re-chill and recut.	Gray <sup>11</sup>
Carleton	0.2% Teepol (or other wetting agent) in water	Place the trimmed block surface in solution for a few minutes, rinse in cold water, re-chill and recut.	Drury and Wallington <sup>6</sup>
Goodwin	Ethanol 5 parts Glycerol 5 parts Teepol 1 part	Recommended for decalcified bone or dense fibrous tissue. Claims that soaking overnight or longer did not damage blocks	Goodwin <sup>29</sup>
Fabric softener	Downy Fabric Softener 5 ml Distilled water 100 ml Mix well, place in labelled specimen container. Stable for 2 months.	Place block face down into solution. Allow to soak for 5-10 minutes. Can also be used to wipe the face of the block prior to each section.	WebPath <sup>20</sup>
Mollifex	Water, ethanol, methanol, acetone, glycerol, 4-hexylresorcinol	Place the trimmed block surface in Mollifex for a few minutes, rinse in water, re-chill and recut.	Culling <sup>21</sup> Gray <sup>11</sup> MSDS <sup>30</sup>
Potassium hydroxide	10% aqueous potassium hydroxide	Can be used to soften nail and dense keratin after formalin fixation prior to processing and also on paraffin blocks. Place block face down into solution. Allow to soak for a few minutes, thoroughly rinse in water, re-chill and recut.	Winsor <sup>22</sup>
Phenol	4% aqueous phenol	Place block face down into solution. Allow to soak for a few minutes, thoroughly rinse in water, re-chill and recut.	Winsor <sup>22</sup>



Method	Composition	Application	Reference
Ammonia/ Tween Softner	Equal volume mixture of 5% aqueous ammonia and 5% aqueous Tween <sup>80</sup>	Place block face down into solution. Allow to soak for a few minutes, thoroughly rinse in water, re-chill and recut.	Dorevitch Pathology (Melbourne)
Nair or Veet	Thioglycolate formulas that break the disulphide bonds in keratin	Cover block face with lotion. Allow to soak for a few minutes, rinse in water, re-chill and recut.	Winsor <sup>22</sup>

**Table 6. Reconstitution, restoration or softening agents for use on specimens**

Method	Composition	Application	Reference
Mekota(used to reconstitute mummified tissue)	0.2% Comfort fabric softener in 5% sodium carbonate 80 ml 4% formaldehyde (10% formalin) 20 ml	Overnight immersion followed by 24 hours formalin fixation, then process normally.	Mekota <sup>24</sup>
Baker (used during processing or applied to the cut surface of a paraffin block)	60% ethanol 90 ml Glycerol 10 ml	Soak block until tissue softens (1 to 24 hours) then process normally.	Gray <sup>11</sup>
Anderson and Gordon(for restoration of tissue dried in processing)	70% ethanol 70 ml Glycerol 30 ml Dithionite 1 g	Soak tissues for several hours, usually overnight then process from the dehydration stage in the usual manner.	Bancroft and Stevens <sup>10</sup>
Sandison(softening of dehydrated, dessicated, brittle or unusually hard fixed or mummified gross tissue specimens)	96% ethanol 30 ml 1% aq. formalin 50 ml 5% aq. sodium carbonate 20 ml	Soak tissues for 12 to 18 hours, then process from the dehydration stage in the usual manner.	Thompson <sup>18</sup>

<b>Method</b>	<b>Composition</b>	<b>Application</b>	<b>Reference</b>
Luna (softening tissue dried before or after fixation – including dried cadaver tissue, and for poorly processed tissue)	Formol-sodium acetate stock solution: Formalin (38% formaldehyde) 10 ml Sodium acetate 2 g Water 90 ml Formol-glycerol working solution: Formol-sodium acetate stock 90 ml Glycerol 10 ml	Soak until tissue becomes soft (usually 5 – 8 hours) Extended exposure will not harm tissue. Process in the usual manner.	Luna <sup>15</sup>
Epitope Retrieval Solution (BOND Epitope Retrieval Solution 2) or Tris buffer	ER solution pH 9 diluted as recommended or Tris – HCl buffer pH 9	Soak tissue for 1 – 12 hours depending on size, type and state of the specimen. Incubation at 65°C may accelerate the action of these agents.	Wright <sup>31, 32</sup>
Isotonic Saline	0.85% aqueous sodium chloride	Soak tissue for 1 – 12 hours depending on size, type and state of the specimen. Incubation at 65°C may accelerate the action of this agent.	
Neutral Buffered Formalin	10% formalin in phosphate buffer at pH 7.4	Soak tissue for 1 – 12 hours depending on size, type and state of the specimen.	





## References

1. Rolls GO, Farmer NJ, Hall JB. Artifacts in Histological and Cytological Preparations. 1st ed. Melbourne: Leica Biosystems, 2008.
2. Luna LG. Questions in search of an answer (Question 4). *HistoLogic* 1988;XVIII;16.
3. Dayman ME. Response to questions in search of an answer. *HistoLogic* 1989;XIX;56 - 57.
4. Grizzle WE. The effect of tissue processing variables other than fixation on histochemical staining and immunohistochemical detection of antigens. *The Journal of Histotechnology* 2001;24;213-219.
5. Wynnchuk M. An Artifact of H&E Staining: The Problem and Its Solution. *The Journal of Histotechnology* 1990;13;193-198.
6. Drury RAB, Wallington EA. *Carleton's Histological Technique*. 5th ed. Oxford: Oxford University Press, 1980.
7. Faolain EO, Hunter MB, Byrne JM et al. Raman spectroscopic evaluation of efficacy of current paraffin wax section dewaxing agents. *Journal of Histochemistry and Cytochemistry* 2005;53;121-129.
8. Disbrey BD, Rack JH. Dehydration and clearing. *Histological Laboratory Methods*. Edinburgh: E. & S. Livingstone, 1970;43.
9. Clapp TR, Mellen PF. Rapid "Reprocessing" of Poorly Prepared Fatty Tissues. *The Journal of Histotechnology* 1998;21;65.
10. Anderson G, Gordon KC. Tissue processing, microtomy and paraffin sections. In Bancroft JD and Stevens A eds. *Theory and Practice of Histological Techniques*. New York: Churchill Livingstone, 1996;57.
11. Gray SJ. *Practice of microtomy. Essentials of Microtomy*. London: Butterworths, 1972;72.
12. Humason G. Paraffin sectioning and mounting. *Animal Tissue Techniques*. San Francisco: W H Freeman and Company, 1972;61.
13. Johnson ml. A technique for correcting poorly processed paraffin blocks. *Histologic* 2003;XXXVI;21-22.
14. Lefebvre G. Reprocessing tissue blocks. *Histologic* 2001;XXXIV;42.
15. Luna LG. Method for reprocessing dried tissue specimens. *Histologic* 1978;VIII;111.
16. Mondragon G. Facts about alcohol dehydration of tissue samples. *Histologic* 2006;XXXIX;23.
17. Staples TC. Rehydration of biopsy specimens to facilitate sectioning. *Histologic* 1996;XXVI.
18. Thompson SW. Preparation of microscopic tissue sections. *Selected Histochemical and Histopathological Methods*. Springfield: Charles C Thomas, 1966;137-138.
19. Taggart G. Taggart's reprocessing technique. Sydney: Email to G Rolls, August 6, 2008.
20. WebPath: Internet Pathology Laboratory. Downy: Block softening solution. The University of Utah Eccles Health Sciences Library 2008; <http://library.med.utah.edu/WebPath/webpath.html>; January 19, 2009
21. Culling CFA, Allison RT, Barr WT. *Cellular Pathology Technique*. 4th ed. London: Butterworths, 1985.
22. Winsor L. Tissue Processing. In Woods AE and Ellis RC eds. *Laboratory Histopathology*. New York: Churchill Livingstone,

1994;4:2-37.

23. Leica. Paraffin Tape Transfer System. MyNeuroLab.com, 2009; <http://www.myneurolab.com/myneurolab/Products/ProductList.aspx/Histology+Products/Paraffin+Tape+Transfer+System/4/232>;
24. Mekota AM, Grupe G, Zimmerman MR, Vermehren M. First identification of an ancient Egyptian mummified human placenta. *International Journal of Osteoarchaeology* 2005;15:51-60.
25. Ciranni R, Castagna M, Fornaciari G. Goiter in an eighteenth-century Sicilian mummy. *American Journal of Physical Anthropology* 1999;108:427-432.
26. Verbov JL. Mummified skin - an exercise in preservation. *International Journal of Dermatology* 1983;22:46-60.
27. Carson FL. *Histotechnology: A self-instructional text*. 2nd ed. Chicago: ASCP Press, 1997.
28. Rolls GO, Farmer NJ, Tarbet F. Assessing the Quality of Tissue Processing and the Performance of PELORIS using the Leica Biosystems Scoring System. *Scientia Educational Materials and White Papers*, 2005.
29. Goodwin JR. Strict serial sectioning with particular reference to bone and dense fibrous tissue. *Histologic* 1981;XI 1-2.
30. EMD Chemicals Inc. Mollifex Material Safety Data Sheet. 2008; [http://www.emdchemicals.com/analytics/doc/msds/MSDSU\\_65039.htm](http://www.emdchemicals.com/analytics/doc/msds/MSDSU_65039.htm); January 19, 2009
31. Wright KR. Research Antigen Retrieval Solution (Letter to the Editor). *The Journal of Histotechnology* 1994;17;81.
32. BioGenix. Data Sheet: H&E Retrieval Solution Cat No HK168-5K. San Ramon, Ca: BioGenix, 2004.







**LeicaBiosystems.com**



Knowledge Pathway is a scientific and educational resource for professionals in the Anatomic Pathology field. Built by a steadily growing community of authors and experts, this lively science portal continuously offers you new and relevant information, ranging from the basics to specific application know-how.

[knowledgepathway.com](http://knowledgepathway.com)

---

## LEICA BIOSYSTEMS

Leica Biosystems is a global leader in workflow solutions and automation, integrating each step in the workflow. As the only company to own the workflow from biopsy to diagnosis, we are uniquely positioned to break down the barriers between each of these steps. Our mission of "Advancing Cancer Diagnostics, Improving Lives" is at the heart of our corporate culture. Our easy-to-use and consistently reliable offerings help improve workflow efficiency and diagnostic confidence. The company is represented in over 100 countries and is headquartered in Nussloch, Germany.

Copyright © 2021 Leica Biosystems, a division of Leica Microsystems Inc. All rights reserved.  
LEICA and the Leica Logo are registered trademarks of Leica Microsystems IR GmbH. Other logos,  
product and/or company names might be trademarks of their respective owners.